

Anti-interleukin-6 Receptor Antibody (Tocilizumab) Treatment of Multicentric Castleman's Disease

Masashi Matsuyama, Takeshi Suzuki, Hiroto Tsuboi, Satoshi Ito, Mizuko Mamura, Daisuke Goto, Isao Matsumoto, Akito Tsutsumi and Takayuki Sumida

Abstract

We report three cases of multicentric Castleman's disease (MCD) successfully treated with anti-interleukin-6 receptor antibody (tocilizumab). Tocilizumab was administered intravenously at a dose of 8 mg/kg every 2 weeks. In each case, tocilizumab alleviated symptoms, including generalized fatigue, pyrexia, and alleviated biochemical abnormalities, including anemia, hypoalbuminemia, hypergammaglobulinemia, and increased C-reactive protein (CRP). Side effects included hypercholesterolemia, acute pyelonephritis, mild inflammation of the parotid glands, and upper respiratory system inflammation. Other severe side effects were not observed. These results indicate that tocilizumab is effective for the treatment of MCD. This is the first report on tocilizumab efficacy for Castleman's disease after approval for use for Castleman's disease.

Key words: multicentric Castleman's disease, anti-interleukin-6 receptor antibody, tocilizumab

(DOI: 10.2169/internalmedicine.46.6262)

Introduction

Castleman's disease is a lymphoproliferative disorder with benign hyperplastic lymph nodes; it is characterized histologically as hyaline vascular-type, plasma cell-type, or mixed-type (1). Patients with the plasma cell- or mixed-type Castleman's disease frequently experience systemic manifestations such as pyrexia, generalized fatigue, loss of appetite, weight loss, night sweats, splenomegaly, hepatomegaly, and skin rash (1). Abnormal laboratory findings include anemia, hypoalbuminemia, hypocholesterolemia, hypergammaglobulinemia, and increased levels of acute phase proteins (1). Localized Castleman's disease is termed unicentric Castleman's disease (UCD) and is curable by excision of the affected lymph nodes. However, multicentric Castleman's disease (MCD) is often refractory to treatment even with corticosteroids or chemotherapy. MCD is non-neoplastic, but the prognosis is poor without treatment.

Interleukin-6 (IL-6) is a cytokine with a wide range of biologic activities; it regulates immunologic reactions, inflammatory responses, and hematopoiesis. Overproduction of IL-6 by germinal center B cells is implicated in the

pathogenesis of MCD (2, 3). Previous studies showed that anti-IL-6 antibody or anti-IL-6 receptor antibody (tocilizumab) dramatically alleviated symptoms and biochemical abnormalities of MCD (4-6). Tocilizumab was approved in Japan for the treatment of Castleman's disease in June 2005. A phase II study evaluating the long-term efficacy and safety of tocilizumab in the treatment of MCD will continue until 2007. We evaluated the effect of tocilizumab in three cases of MCD. These are the first case reports since the approval of tocilizumab in Japan.

Case Report

Three patients diagnosed with MCD were administered tocilizumab intravenously at a dose of 8 mg/kg every 2 weeks at Tsukuba University Hospital. Each patient showed lymphadenopathy at multiple sites, pyrexia, and generalized fatigue. Laboratory findings included anemia, hypoalbuminemia, hypergammaglobulinemia, an increased CRP level, and an increased IL-6 level. All patients had been diagnosed with plasma cell-type Castleman's disease on the basis of histologic examination of biopsy specimens. Clinical characteristics of the patients are listed in Table 1. All three pa-

Table 1. Clinical Profiles of the Three Patients in this Study

Case	Sex	Age (years)	Disease duration (years)	Lymphadenopathy	Pathology	Serum IL-6 (pg/ml)	First therapy
1	Female	59	8.9	Maximum axis, 20 mm in cervical, axillary, and inguinal lymph nodes	Plasma-cell type	162	PSL 30 mg/day
2	Female	43	2.7	Maximum axis, 25 mm in intraperitoneal lymph nodes	Plasma-cell type	77.9	PSL 40 mg/day
3	Female	41	1.3	Maximum axis, 25 mm in systemic lymph nodes	Plasma-cell type	27.4	PSL 40 mg/day

PSL, prednisolone

tients had previously been treated with prednisolone (PSL) or immunosuppressive therapy for more than 1 year.

Case 1

A 52-year-old woman was admitted to Tsukuba University Hospital in 1998, and MCD was diagnosed on the basis of histologic examination of biopsy specimens. The serum level of IL-6 was 162 pg/ml (the normal upper limit is 4 pg/ml). The patient was discharged and administered PSL and azathioprine (AZP) on an outpatient basis. PSL and AZP alleviated generalized fatigue, low-grade fever, skin rash, and lymphadenopathy but did not ameliorate biochemical abnormalities. We therefore administered tocilizumab from September 21, 2005. Tocilizumab alleviated biochemical abnormalities. We discontinued AZP and tapered PSL from 15 mg/day to 6 mg/day. A decrease in the size of swollen lymph nodes was maintained after treatment with tocilizumab despite tapering of PSL. However, atorvastatin therapy was initiated because hypercholesterolemia occurred as a side effect of tocilizumab treatment.

Case 2

A 40-year-old woman was admitted to Tsukuba University Hospital in 2003, and MCD was diagnosed on the basis of histologic examination of biopsy specimens. Laboratory tests showed increased IL-6 (77.9 pg/ml). Immunostaining for cluster of differentiation 20 (CD20) was slightly positive. The patient was discharged and administered PSL on an outpatient basis. PSL alleviated systemic symptoms, such as erythema and lymphadenopathy, and ameliorated biochemical abnormalities. However, biochemical abnormalities appeared again with the tapering of PSL. Severe osteoporosis

occurred; therefore, we could not increase the dose of PSL. Thus, we administered tocilizumab from September 7, 2005. Tocilizumab alleviated the biochemical abnormalities. We were able to taper PSL from 10 mg/day to 8 mg/day. A decrease in the size of swollen lymph nodes was maintained after treatment with tocilizumab despite tapering of PSL. Mild inflammation of the parotid glands occurred as a side effect of tocilizumab but was eliminated by antibiotic treatment.

Case 3

A 37-year-old woman was admitted to Tsukuba University Hospital in May 2002, and MCD was diagnosed on the basis of histologic examination of biopsy specimens. Immunostaining for CD20 was slightly positive. The serum level of IL-6 was increased to 27.4 pg/ml. Results of polymerase chain reaction (PCR) for human herpes virus 8 (HHV-8) were negative. The patient was discharged and administered PSL on an outpatient basis. PSL alleviated systemic symptoms such as generalized fatigue and lymphadenopathy but did not ameliorate biochemical abnormalities. We therefore administered tocilizumab beginning October 19, 2005 (Fig. 1). Tocilizumab alleviated biochemical abnormalities. We were able to taper PSL from 17.5 mg/day to 9 mg/day. A decrease in the size of swollen lymph nodes was maintained after treatment with tocilizumab despite tapering of PSL. On December 14, 2005, upper respiratory inflammation occurred, and the tocilizumab was stopped. On December 28, 2005, symptoms of upper respiratory inflammation had disappeared, but the CRP level had increased to 13.0 mg/dl. We suspected exacerbation of MCD due to tocilizumab withdrawal and therefore resumed treatment. The

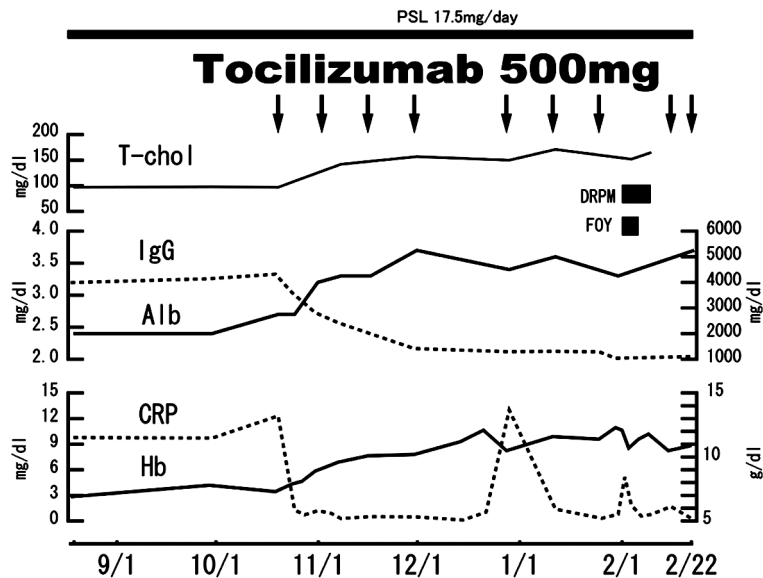


Figure 1. Clinical course of case 3. PSL, prednisolone; T-CHO, total cholesterol; IgG, immunoglobulin G; Alb, albumin; Hb, hemoglobin; CRP, C-reactive protein; DRPM, doripenem; FOY, gabexate mesilate.

CRP level decreased to 0.31 mg/dl by January 25, 2006.

On January 30, 2006, after 5 days of tocilizumab injection, pyrexia, lumbalgia, a constant urge to urinate and generalized fatigue occurred, and acute pyelonephritis was diagnosed by urinalysis. The white blood cell (WBC) count was 11,000/ μ l, and the CRP level was 0.79 mg/dl. In early February 2006, the patient was admitted to Tsukuba University Hospital because of the increase in CRP after treatment with tocilizumab and suspicion of disseminated intravascular coagulation (DIC) due to increased levels of fibrin degradation products and a decreased platelet count. The tocilizumab was again stopped. The DIC score was only 2 points, but the patient was treated with antibiotics (doripenem) and gabexate mesilate and subsequently discharged.

Serum Levels of IL-6

IL-6 levels decreased dramatically after treatment with PSL in the 3 cases; the average IL-6 level decreased from 89.1 pg/ml to 7.4 pg/ml. However, IL-6 levels increased after treatment with tocilizumab; the average IL-6 level increased from 7.4 pg/ml to 205 pg/ml.

Discussion

There are many therapies for MCD, such as steroids, chemotherapy, combination chemotherapy, antiviral agents, interferon alpha, antibodies to IL-6, rituximab (monoclonal CD20 antibody), and tocilizumab. However, treatment recommendations for MCD can be difficult because there is no standard therapy, and the literature consists of single case reports and small case series (4, 6-10). A recent review suggested that valganciclovir should be considered for HHV-8 PCR-positive patients, rituximab for CD20-positive patients,

and cyclophosphamide, doxorubicin, vincristine, PSL (CHOP), thalidomide, interferon-alpha, or PSL for HHV-8 PCR-negative and CD20-negative patients (11). Testing for HHV-8 PCR was performed only in case 3, and the results were negative. Immunostaining for CD20 was performed in cases 2 and 3 and it was slightly positive in both.

In the patients reported here, tocilizumab dramatically ameliorated biochemical abnormalities after 18 weeks of treatment. The average CRP level of the three patients decreased from 8.51 mg/dl to 0.06 mg/dl. The average IgG level decreased from 3,509 mg/dl to 1,517 mg/dl. The average albumin level increased from 3.2 mg/dl to 4.2 mg/dl. The hemoglobin level increased markedly, except for case 2. IL-6 levels decreased dramatically after treatment with PSL in the 3 cases. However, IL-6 levels increased after treatment with tocilizumab, and the average IL-6 level increased again. This may be due to venal pooling of unused IL-6 in response to blocking of IL-6 receptors by tocilizumab.

A recent study of tocilizumab for MCD from the date of approval to June 30, 2006, suggested an absence of severe and unexpected side effects, as in the phase II study (12). This study, which was a postmarketing surveillance for MCD in Japan, consisted of 132 cases. Major side effects were infection (55/132) and abnormal laboratory values (60/132), including hypercholesterolemia (4/132) and hypertriglycemia (5/132). Side effects of tocilizumab in these 3 cases were hypercholesterolemia, acute pyelonephritis, and mild inflammation of the parotid glands and upper respiratory system. Other severe side effects were not observed. Nishimoto et al (5) reported that side effects of tocilizumab include urinary tract infection (14.3% of enrolled patients). We also observed acute pyelonephritis with suspected DIC as a side effect of tocilizumab. However, the CRP level was

not markedly increased; the maximum CRP was 5.14 mg/dl, despite severe urinary tract infection. Tocilizumab may mask increased CRP levels associated with infection because IL-6 is a hepatocyte-stimulating factor that induces CRP production. An increased WBC count is an effective marker for inflammation. However, in case 3, we were not able to detect inflammatory increases in the WBC count because PSL increased the count from 10,000/ μ l to 15,000/ μ l. Therefore, infection should be diagnosed as a result of detailed physical and biochemical examinations, and hospitalization may be required despite little or no increase in the CRP level (13, 14).

In the present patients, PSL treatment dramatically ameliorated physical symptoms and decreased IL-6 levels and lymphadenopathy without biochemical abnormalities. Thus, these 3 patients were responsive to PSL. However, we were not able to continue administration of high-dose PSL be-

cause of side effects. We were able to decrease the dose of corticosteroids or discontinue immunosuppressants after treatment with tocilizumab. Decreased swelling of lymph nodes was maintained after treatment with tocilizumab, even with tapering of PSL. However, tocilizumab did not decrease swelling of lymph nodes after PSL treatment. It should be noted that the high cost of continuous tocilizumab treatment has been a difficulty for these patients.

Results in these 3 cases support the effectiveness of tocilizumab in patients with MCD. We suggest that tocilizumab should be used for HHV-8 PCR-negative and CD20-negative patients unresponsive to PSL or for patients experiencing undesirable side effects of PSL. In addition, rituximab was not currently approved in Japan for the treatment of MCD. Therefore, tocilizumab will play an important role in the treatment of MCD in Japan.

References

1. Peterson BA, Frizzera G. Multicentric Castleman's disease. *Semin Oncol* **20**: 636-647, 1993.
2. Yoshizaki K, Matsuda T, Nishimoto N, et al. Pathogenic significance of interleukin-6 (IL-6/BSF-2) in Castleman's disease. *Blood* **74**: 1360-1367, 1989.
3. Nishimoto N. Clinical studies in patients with Castleman's disease, Crohn's disease, and rheumatoid arthritis in Japan. *Clin Rev Allergy Immunol* **28**: 221-230, 2005.
4. Nishimoto N, Sasai M, Shima Y, et al. Improvement in Castleman's disease by humanized anti-interleukin-6 receptor antibody therapy. *Blood* **95**: 56-61, 2000.
5. Nishimoto N, Kanakura Y, Aozasa K, et al. Humanized anti-interleukin-6 receptor antibody treatment of multicentric Castleman disease. *Blood* **106**: 2627-2632, 2005.
6. Beck JT, Hsu SM, Wijdenes J, et al. Brief report: alleviation of systemic manifestations of Castleman's disease by monoclonal anti-interleukin-6 antibody. *N Engl J Med* **330**: 602-605, 1994.
7. Corbellino M, Bestetti G, Scalamogna C, et al. Long-term remission of Kaposi sarcoma-associated herpesvirus-related multicentric Castleman disease with anti-CD20 monoclonal antibody therapy. *Blood* **98**: 3473-3475, 2001.
8. Ocio EM, Sanchez-Guijo FM, Diez-Campelo M, et al. Efficacy of rituximab in an aggressive form of multicentric Castleman disease associated with immune phenomena. *Am J Hematol* **78**: 302-305, 2005.
9. Pavlidis NA, Skopouli FN, Bai MC, Bourantas CL. A successfully treated case of multicentric angiofollicular hyperplasia with oral chemotherapy (Castleman's disease). *Med Pediatric Oncol* **18**: 333-335, 1990.
10. Dispenzieri A, Gertz MA. Treatment of Castleman's disease. *Curr Treat Options Oncol* **6**: 255-266, 2005.
11. Casper C. The aetiology and management of Castleman disease at 50 years: translating pathophysiology to patient care. *B J Haematol* **129**: 3-17, 2005.
12. Actemra Intravenous Infusion 200 Safety Information Tabulation Results From Approval to June 30 2006 (published Oct. 2006).
13. Nishimoto N. The therapeutic efficacy of tocilizumab for rheumatoid arthritis. *Rheumatology* **35**: 409-412, 2006 (in Japanese).
14. Actemra Intravenous Infusion 200 Information concerning the appropriate use (second edition: published Jul. 2005).