

Castleman Disease Pathogenesis



David C. Fajgenbaum, MD, MBA, MSc*, Dustin Shilling, PhD

KEYWORDS

- Castleman disease • Lymphoproliferative disorder • HHV-8 • POEMS • TAFRO
- Cytokine storm

KEY POINTS

- Castleman disease (CD) is subclassified based on the number of enlarged lymph nodes, Kaposi sarcoma–associated herpesvirus/human herpesvirus-8 (HHV-8) infection status, and clinical presentation.
- The pathogenesis of unicentric CD (adenopathy of a single region of lymph nodes) is most likely driven by a neoplastic follicular dendritic cell population.
- HHV-8–associated multicentric CD (adenopathy of multiple regions of lymph nodes) pathogenesis is virally driven, whereas polyneuropathy, organomegaly, endocrinopathy, monoclonal plasma cell disorder, and skin changes (POEMS)–associated multicentric CD (MCD) pathogenesis is driven by a monoclonal plasma cell population.
- Idiopathic MCD is poorly understood, although clinical data suggest a pathologic role for interleukin-6 in a subset of patients.

INTRODUCTION

Castleman disease (CD) describes a heterogeneous group of disorders defined by shared lymph node histopathological features, including atrophic or hyperplastic germinal centers, prominent follicular dendritic cells (FDCs), hypervascularization, polyclonal lymphoproliferation, and/or polytypic plasmacytosis.¹ Complicating diagnosis, these histopathologic features are not unique to CD but can be observed in other diseases as well.² Each subtype of CD has varying clinical features, causes, treatments, and outcomes. This article establishes the nomenclature required to discuss the different subtypes of CD (**Fig. 1**) and provides a summary of our current

Disclosure: D.C. Fajgenbaum receives research funding from Janssen Pharmaceuticals. D. Shilling has nothing to disclose.

Division of Translational Medicine and Human Genetics, Hospital of the University of Pennsylvania, 3400 Spruce Street, Silverstein 5, Suite S05094, Philadelphia, PA 19104, USA

* Corresponding author.

E-mail address: davidfa@pennmedicine.upenn.edu

Hematol Oncol Clin N Am 32 (2018) 11–21

<https://doi.org/10.1016/j.hoc.2017.09.002>

0889-8588/18/© 2017 Elsevier Inc. All rights reserved.

hemonc.theclinics.com

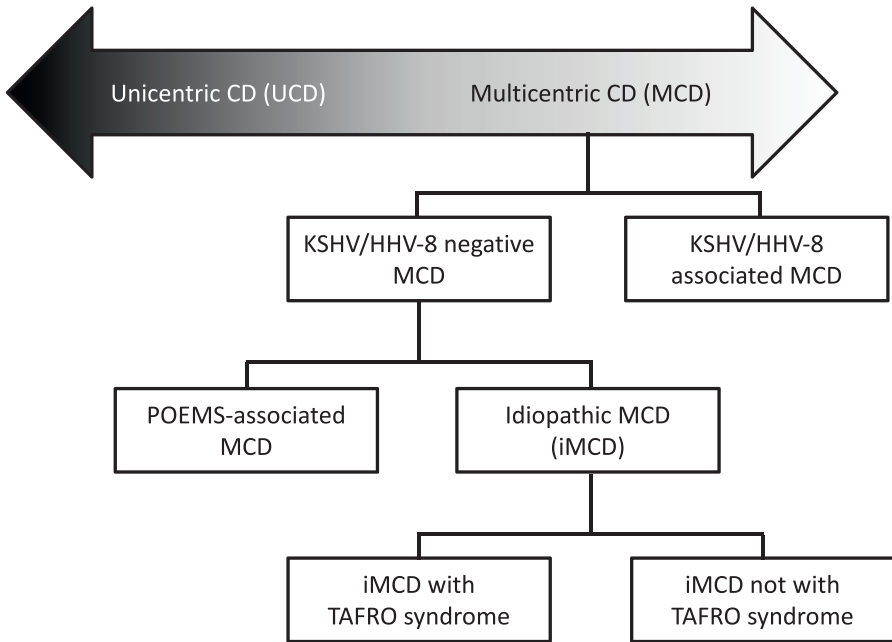


Fig. 1. CD classification. CD is classified based on the number of sites of enlarged lymph nodes with CD histopathological features. On one side of the CD spectrum is unicentric CD (UCD), solitary lymphadenopathy. On the other side of the spectrum is multicentric CD (MCD), multiple sites of lymphadenopathy. A hybrid of UCD and MCD, regionally restricted lymphadenopathy, has also been rarely observed. MCD is segmented based on Kaposi sarcoma-associated herpesvirus (KSHV)/human herpesvirus-8 (HHV-8) status. HHV-8-negative MCD is categorized as either *polyneuropathy, organomegaly, endocrinopathy, monoclonal plasma cell disorder, and skin changes* (POEMS)-associated or idiopathic MCD, the latter of which can be either with or without thrombocytopenia, anasarca, myelofibrosis, renal dysfunction, and organomegaly (TAFRO) syndrome.

understanding of the cause, cell types, signaling pathways, and effector cytokines implicated in pathogenesis.

CD is first classified based on the number of regions of enlarged lymph nodes that demonstrate histopathologic features consistent with CD. Unicentric CD (UCD) involves a single enlarged lymph node or region of lymph nodes, whereas multicentric CD (MCD) involves multiple regions of enlarged lymph nodes.

MCD is further divided based on Kaposi sarcoma-associated herpesvirus (KSHV)/human herpesvirus-8 (HHV-8) infection status. In HHV-8-positive MCD, uncontrolled HHV-8 infection signals for excessive cytokine production, which causes the clinical and pathologic abnormalities.³ Monoclonal plasma cells underlying coexisting *polyneuropathy, organomegaly, endocrinopathy, monoclonal plasma cell disorder, and skin changes* (POEMS) syndrome cause some cases (POEMS-associated MCD) of HHV-8-negative MCD, whereas others are idiopathic (iMCD). POEMS is a paraneoplastic syndrome that often co-occurs with MCD (POEMS-associated MCD).⁴ iMCD is itself heterogeneous; recent work has identified at least one distinct clinical subtype of iMCD, which involves thrombocytopenia, anasarca, myelofibrosis, renal dysfunction, and organomegaly (TAFRO) syndrome (iMCD-TAFRO).⁵

UNICENTRIC CASTLEMAN DISEASE

Most patients with UCD do not experience systemic symptoms.¹ Typically, the enlarged lymph node will be discovered inadvertently, during care for another condition or because it is impeding on nearby organs. UCD is diagnosed by histopathologic examination of the excised lymph node. Removal of the node or region of nodes is almost always curative, but recurrences of UCD have been reported.⁶ Thus, it is thought that the pathologic cell types and drivers are present in the excised lymph node. No cases of UCD have ever been reported to transition into MCD.

Cause

Viral, neoplastic, and reactive inflammatory mechanisms have all been proposed as etiologic mechanisms in UCD. Arguing against the viral hypothesis, T-Box Expressed in T cells, which is expressed by cells in the context of high interferon- γ during intracellular pathogen infection, was not found to be expressed by T or B cells in UCD lymph nodes.⁷ In one study, all UCD lymph nodes were found to be Epstein-Barr virus (EBV) positive,⁸ but this observation was not reproduced in a separate cohort.⁹ Given the high prevalence of EBV infection and rarity of UCD, it is unlikely that EBV is a primary pathologic driver of UCD.

In contrast to the viral hypothesis, several lines of evidence suggest that UCD is most likely neoplastic. A study of lymphoproliferative disorders found that UCD lymph nodes have an increased number of small follicles with abnormally low proliferation, which is observed in follicular lymphoma so the investigators concluded this finding may be suggestive of neoplastic changes.¹⁰ UCD is one of the most common causes of paraneoplastic pemphigus along with non-Hodgkin lymphoma and other hematologic neoplasia.¹¹ Cytogenetic anomalies have been reported in cultured lymph node stromal cells from several UCD cases.^{12–15} In fact, one study identified modifications in chromosome segment 12q13 to 15, which is also commonly found in several benign mesenchymal tumors; another study identified a clonal cytogenetic anomaly (t[1;22] [p22;q13]) that was hypothesized to affect the megakaryoblastic leukemia 1 (MKL1) gene, which is implicated in acute megakaryocytic leukemia, and the endothelial cell growth factor 1 gene, which promotes angiogenesis and prevents cellular apoptosis. However, the most compelling evidence for the neoplastic hypothesis comes from a larger study that used conventional and methylation-specific polymerase chain reaction methods to assess monoclonality within UCD lymph node tissue. Monoclonality was detected in 19 of 25 UCD cases but not in 20 cases of lymphoid hyperplasia.¹⁶ Rare reports of familial cases of UCD do exist, although genetic sequencing was not performed.^{17,18}

Cell Type

The cell type responsible for driving UCD pathogenesis has not been definitively identified. However, the studies described earlier suggest the monoclonal cell harboring the genomic alterations may be stromal, specifically FDCs.^{12,14–16} Consistent with these results, stromal cell overgrowth and FDC prominence and dysplasia are often seen in UCD.¹⁹ FDCs are essential for germinal center formation and play a major role in directing lymphocytes into the appropriate regions within the lymph node and promoting B cell survival.²⁰ In further support of a role for neoplastic FDCs as a primary driver of UCD pathogenesis are reports of patients with UCD subsequently developing FDC sarcoma in the same region of lymph nodes.^{21,22}

Signaling Pathways

Dysregulated signaling pathways have not been extensively studied in UCD. Cases describing overexpression of epidermal growth factor receptor²¹ and interleukin

(IL)-6²³ may shed light on potential signaling pathways involved in other patients with UCD.

Effector Cytokines

In the small portion of UCD cases with systemic symptoms, IL-6 is likely to be the effector cytokine driving systemic symptoms.²⁴ However, IL-6 levels have not been systematically studied in several UCD cases and many cases do not have systemic symptoms. Interestingly, FDCs' role in orchestrating lymphocyte trafficking is largely mediated through the secretion of chemokine (C-X-C motif) ligand 13 (CXCL13) (also known as B lymphocyte chemoattractant), and dysplastic FDCs in UCD lymph nodes strongly express this chemokine.²² Therefore, CXCL13 may play an important role in UCD; but again, CXCL13 levels have not been systematically studied in UCD.

Taken together, experimental data and pathologic characteristics suggest a clonal proliferation of FDCs as the etiologic driver and pathologic cell type in UCD. The authors propose that acquired mutations in these stromal cells result in UCD. Additional studies are needed to investigate this hypothesis.

HUMAN HERPESVIRUS-8–ASSOCIATED MULTICENTRIC CASTLEMAN DISEASE

Although lymph node histopathologic features overlap with those observed in UCD, MCD involves multiple regions of enlarged nodes. Patients with MCD also experience systemic symptoms, including progressive disease flares characterized by constitutional symptoms, cytopenias, hepatosplenomegaly, fluid accumulation, and cytokine storm–associated multiple organ system dysfunction. As detailed in the introduction of this article, MCD is categorized as either HHV-8–associated MCD, POEMS-associated MCD, or iMCD, each of which is discussed independently.

Cause

HHV-8 is the well-established etiologic cause of HHV-8–associated MCD.²⁵ Human immunodeficiency virus (HIV) infection or another cause of immunodeficiency enables HHV-8 to escape from host immune control, lytically replicate in lymph node plasmablasts, and signal for the release of cytokines that drive clinical and pathologic symptoms.^{26,27}

Cell Type

HHV-8 infects B cells and plasmablasts, which can be detected by immunohistochemical staining of patients' lymph node for latency-associated nuclear antigen-1. Highlighting the critical role of B cells in HHV-8–associated MCD, their depletion with rituximab is a highly effective therapy.²⁸ Peripheral T cell levels, including polyfunctional effector memory CD8⁺ T cells, have also been associated with HHV-8–associated MCD pathogenesis.²⁹

Signaling Pathways

Researchers have found that upregulation of nuclear factor kappa-light-chain-enhancer of activated B cells (NF- κ B) by latently expressed viral-FLICE (viral Fas-associating protein with death domain–like interleukin-1–converting enzyme) inhibitory protein or viral microRNA-K1 and upregulation of vascular endothelial growth factor (VEGF) and other factors by a viral G-protein couple receptor may be involved in HHV-8–associated MCD pathogenesis.³⁰ These secreted proteins induce B cell and plasma cell proliferation, angiogenesis, and an acute-phase reaction.²⁵

Effector Cytokines

Human IL-6 and viral IL-6 (vIL-6) both play important roles in driving the B cell proliferation and symptoms observed in HHV-8-associated MCD. Mechanistically, vIL-6 can bind directly to the IL-6 receptor (gp130) and does not need its coreceptor, gp80, as human IL-6 does.³⁰ Therefore, it is possible that a wider range of cells may be affected by vIL-6 than human IL-6.

HUMAN HERPESVIRUS-8-NEGATIVE MULTICENTRIC CASTLEMAN DISEASE

When HHV-8 infection was first associated with MCD in 1994, the CD research community almost entirely shifted its focus to studying HHV-8-associated MCD. Until recently, there was little recognition that a large proportion of patients with MCD are HHV-8 negative. Despite having a similar incidence to HHV-8-associated MCD,³¹ HHV-8-negative MCD has received a fraction of the research attention and is significantly less well understood. The following discussion presents our current molecular and etiologic understanding of HHV-8-negative MCD, which is subclassified into POEMS-associated MCD and iMCD.

POEMS-Associated Multicentric Castleman Disease

Cause/cell type

POEMS-associated MCD is thought to be caused by cytokine production from monoclonal plasma cells that have undergone genomic events, such as translocations or deletions. Nearly all POEMS cases are λ light chain restricted.⁴ Highlighting the primary role of the monoclonal plasma cell population in POEMS pathogenesis, radiation to an isolated plasmacytoma is often curative.⁴

Signaling pathways/effector cytokines

VEGF is the cytokine that best correlates with disease activity,³² although other cytokines must also contribute because VEGF blockade has provided only mixed results clinically.³³ Other cytokines proposed to drive POEMS symptoms are IL-6, IL-12, transforming growth factor- 1β , and tumor necrosis factor- α .³⁴

Idiopathic Multicentric Castleman Disease

Cause

The cause of iMCD is unknown. The heterogeneity of the disease and overlapping clinical and pathologic abnormalities with other immunologic disorders suggest that multiple processes each involving immune dysregulation and a common pathway of increased cytokines may give rise to iMCD in different subsets of patients.³⁵ In fact, recent work has identified 2 subgroups of patients with iMCD, iMCD-TAFRO and iMCD-non-TAFRO, which may represent different causes. To promote research aimed at uncovering the cause of iMCD, the CD research community, led by the Castleman Disease Collaborative Network (CDCN), recently hypothesized 4 candidate etiologically drivers of iMCD pathogenesis (**Fig. 2**), which are described later.

Autoimmune

iMCD may be due to self-reactive antibodies, which stimulate the release of cytokines. Autoimmune diseases can demonstrate clinical and histopathologic features that are identical to iMCD. Nearly all lymph nodes of patients with rheumatoid arthritis and 15% to 30% of lymph nodes from patients with systemic lupus erythematosus display CD histopathologic features.^{36,37} Patients with iMCD respond to therapies used to treat autoimmune disease, such as anti-IL-6 receptor therapy and cyclosporine.³⁸ Approximately 30% of iMCD case reports found autoantibodies and autoimmunity.³¹

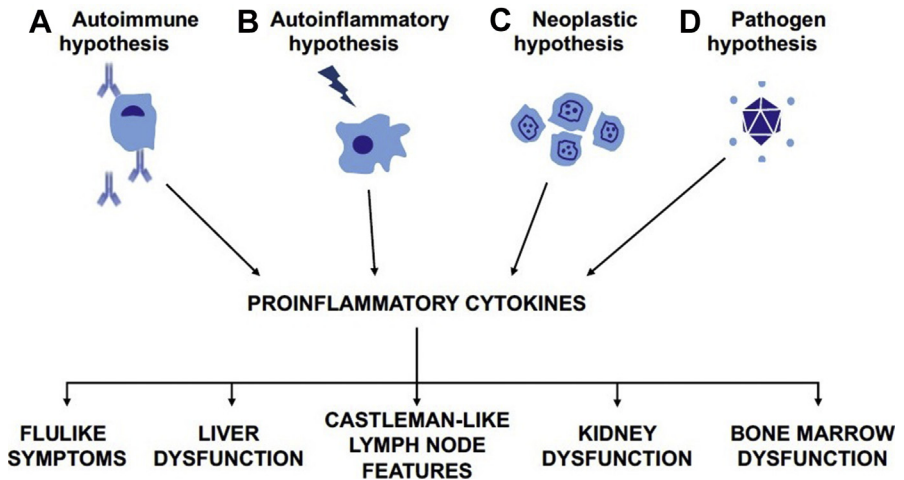


Fig. 2. Hypothesized etiologic drivers of iMCD. The CD research community, led by the CDCN, recently proposed 4 candidate etiologic drivers of iMCD pathogenesis: iMCD may be due to (A) self-reactive antibodies, (B) germline mutations in genes regulating inflammation, (C) acquired oncogenic mutations, or (D) an infection with a pathogen. (Adapted from Supplement to: Fajgenbaum DC, Ruth JR, Kelleher D, et al. The collaborative network approach: a new framework to accelerate Castleman's disease and other rare disease research. *Lancet Haematol* 2016;3(4):e150–2; with permission.)

However, it is unclear if these autoantibodies are etiologically responsible for iMCD, propagators of inflammation, or secondary to a primary disease driver.

Autoinflammatory iMCD may be due to germline mutations in genes regulating inflammation. A germline mutation in the Mediterranean fever gene, often found in familial Mediterranean fever (FMF) syndrome, was described in a reported iMCD case.³⁹ Whether this is a novel genetic cause of iMCD or an atypical case of FMF is unclear. A child with a multicentric Castleman-like syndrome was found to have homozygous mutations in cat eye syndrome critical region protein 1, which encodes adenosine deaminase 2 (ADA2).⁴⁰ Deficiency of ADA2 is known to stimulate IL-6 induction through adenosine A2B receptor activation.⁴¹ An increased proportion of patients with iMCD harbored a polymorphism in the IL-6 receptor (IL-6R) gene compared with healthy controls in a recent study. Individuals with this polymorphism expressed significantly higher levels of soluble IL-6R, which can contribute to increased IL-6 activity through the trans-signaling pathway.⁴² Although interesting, these associations require confirmation and functional analysis.

Neoplastic iMCD may be due to acquired oncogenic mutations. iMCD clinical and histopathologic features overlap with those of lymphoma, and patients with iMCD have an increased rate of malignancy compared with age-matched controls.³¹ Interestingly, in a small study of 4 iMCD cases, all were found to have monoclonality in the lymph node.¹⁶ The monoclonal cells were most likely stromal, as the lymphocytes in those cases were polyclonal and lymphocytes in other MCD cases are typically polyclonal.⁴³ A patient with HIV-negative MCD, who was not tested for HHV-8, was found to have a somatic translocation (46,XY,t[7;14] [p22;q22]) in lymph node tissue at the IL-6 locus (7p21–22).⁴⁴

Pathogen iMCD may be due to an infection. Patients with HHV-8–negative MCD share clinicopathologic features with HHV-8–associated MCD, but a pathogen-driver has

not been discovered to date. Thus, the authors hypothesized that a pathogen, possibly a virus with homology to HHV-8, could be driving iMCD pathogenesis. EBV, HHV-6, hepatitis B virus, cytomegalovirus, toxoplasma, and mycobacterium tuberculosis infection have all been reported in at least one case of iMCD.^{8,45–49} Whether these infections are pathologic, coincidental, or secondary to iMCD immune dysfunction remains to be determined.

Cell type The limited research conducted to date has generated conflicting reports regarding the cell type responsible for driving iMCD pathogenesis and/or producing IL-6. Candidate cell types include lymphocytes, plasma cells, monocytes, endothelial cells, and FDCs.^{23,50–53} Despite the lack of consistent reports, some evidence for a pathogenic role of B cells in some cases does exist. CD5⁺ mantle zone B cells in HIV-negative (HHV-8-unknown) MCD cases proliferate and secrete autoantibodies because of factors produced by fibroblastic reticular dendritic cells.¹⁹ A subset of patients with iMCD respond clinically to B cell depletion with rituximab, supporting B cells as a potential driver or important contributor in some iMCD cases.³¹ However, it is clear that other cell types are involved in iMCD pathogenesis because B cell depletion is not effective in all patients.³¹ Elevated serum soluble IL-2 receptor, a marker of T cell activation, was found in 20 of 21 published cases of iMCD, suggesting a potential role of T cells in iMCD pathogenesis.³¹

Signaling pathways/effector cytokines Although the pathologic cell types in iMCD are unknown, it is clear from human and animal studies that IL-6 is sufficient and, in a subset of patients, necessary to drive iMCD symptomatology, histopathology, and pathogenesis. IL-6 is a pleiotropic cytokine involved in the induction of a wide range of activities, including plasmacytosis, hypergammaglobulinemia, thrombocytosis, acute-phase protein production by the liver, and activation of macrophages and T cells.²⁵ Elevated IL-6 was first associated with iMCD in 1989.⁵² Clinical symptoms often wax and wane with IL-6 levels, which can be highly elevated in patients with iMCD during disease flare.⁵⁴ Mouse models of excess IL-6 production recapitulated many features of human iMCD, and the administration of anti-IL-6R monoclonal antibody (mAb) is effective in treating such mice.^{55,56} Moreover, the administration of recombinant IL-6 to humans can lead to an iMCD-like syndrome.⁵⁷ Interruption of IL-6 signaling with anti-IL-6 or anti-IL-6R mAb is effective at ameliorating symptoms and shrinking lymph nodes in some patients.³¹ Siltuximab, an anti-IL-6 mAb, became the first, and is currently the only, Food and Drug Administration–approved therapy for iMCD based on improved clinical symptoms and lymph node size in 34% of patients compared with 0% for placebo in a double-blind phase II clinical trial.⁵⁸ However, 66% of patients in the clinical trial did not respond to siltuximab treatment, approximately half of which did not have elevated IL-6 levels.⁵⁹ It is, therefore, likely that other cytokines or soluble factors can also drive iMCD pathogenesis. Considering the redundancy of functions played by cytokines, it is certainly plausible that the hypersecretion of similar cytokines could result in a related clinical phenotype.

Evidence has been slowly accumulating for a role of additional cytokines in iMCD pathogenesis. A systematic review of iMCD case reports found that VEGF was elevated in 16 of 20 cases,³¹ a finding that was subsequently confirmed in 17 cases.⁶⁰ Elevated VEGF levels may explain the capillary leak syndrome and eruptive cherry hemangiomas observed in some iMCD cases.⁶¹ Mechanistic target of rapamycin (mTOR), which regulates VEGF expression, has also been implicated, as a relapsed/refractory iMCD-TAFRO case experienced a prolonged remission on the mTOR inhibitor sirolimus.⁵ IL-1 β has also been proposed as a possible driver of iMCD

pathogenesis. Administration of anti-IL-1 therapy has been reported to be effective in a few case reports, including 2 patients with iMCD refractory to anti-IL-6 therapy.^{62,63} IL-1 β is upstream of IL-6 and VEGF in the proinflammatory cascade and leads to IL-6 production through NF- κ B activation. Regardless of cause, excessive activation of inflammatory pathways in immune cells leads to histopathologic changes in the lymph node and systemic symptoms observed in iMCD.

FUTURE DIRECTIONS

This article presents our current understanding of the pathogenesis for each subtype of CD as of 2017. Although our understanding of CD has slowly improved over the last 6 decades, leading to improved patient survival and quality of life, additional research is needed. The authors anticipate significant progress to be made in the coming years through research studies led by the CDCN, including the ACCELERATE (Advancing Castleman Care with an Electronic Longitudinal registry, E-Repository, And Treatment/Effectiveness research) Natural History Registry (www.CDCN.org/ACCELERATE), which is open for patient self-enrollment.

REFERENCES

1. Waterston A, Bower M. Fifty years of multicentric Castleman's disease. *Acta Oncol* 2004;43(8):698–704.
2. Fajgenbaum DC, Uldrick TS, Bagg A, et al. International, evidence-based consensus diagnostic criteria for HHV-8–negative/idiopathic multicentric Castleman disease. *Blood* 2017;129(12):1646–57.
3. Oksenhendler E, Duarte M, Soulier J, et al. Multicentric Castleman's disease in HIV infection: a clinical and pathological study of 20 patients. *AIDS* 1996;10(1):61–7.
4. Dispenzieri A. POEMS syndrome and Castleman's disease. In: Zimmerman TM, Kumar SK, editors. *Biology and management of unusual plasma cell dyscrasias*. New York: Springer; 2017. p. 41–69.
5. Iwaki N, Fajgenbaum DC, Nabel CS, et al. Clinicopathologic analysis of TAFRO syndrome demonstrates a distinct subtype of HHV-8-negative multicentric Castleman disease. *Am J Hematol* 2016;91(2):220–6.
6. Talat N, Schulte KM. Castleman's disease: systematic analysis of 416 patients from the literature. *Oncologist* 2011;16(9):1316–24.
7. Johrens K, Anagnostopoulos I, Durkop H, et al. Different T-bet expression patterns characterize particular reactive lymphoid tissue lesions. *Histopathology* 2006;48(4):343–52.
8. Chen CH, Liu HC, Hung TT, et al. Possible roles of Epstein-Barr virus in Castleman disease. *J Cardiothorac Surg* 2009;4:31.
9. Al-Maghrabi JA, Kamel-Reid S, Bailey DJ. Lack of evidence of Epstein-Barr virus infection in patients with Castleman's disease. *Molecular genetic analysis*. *Neurosciences (Riyadh)* 2006;11(4):279–83.
10. Bryant RJ. Ki67 staining pattern as a diagnostic tool in the evaluation of lymphoproliferative disorders. *Histopathology* 2006;48(5):505–15.
11. Lehman VT, Barrick BJ, Pittelkow MR, et al. Diagnostic imaging in paraneoplastic autoimmune multiorgan syndrome: retrospective single site study and literature review of 225 patients. *Int J Dermatol* 2015;54(4):424–37.
12. Chen WC, Jones D, Ho CL, et al. Cytogenetic anomalies in hyaline vascular Castleman disease: report of two cases with reappraisal of histogenesis. *Cancer Genet Cytogenet* 2006;164(2):110–7.

13. Cokelaere KK. Hyaline vascular Castleman's disease with HMGIC rearrangement in follicular dendritic cells: molecular evidence of mesenchymal tumorigenesis. *Am J Surg Pathol* 2002;26(5):662–9.
14. Pauwels P, Dal Cin P, Vlasveld LT, et al. A chromosomal abnormality in hyaline vascular Castleman's disease: evidence for clonal proliferation of dysplastic stromal cells. *Am J Surg Pathol* 2000;24(6):882–8.
15. Reichard KK, Robinett S, Foucar MK. Clonal cytogenetic abnormalities in the plasma cell variant of Castleman disease. *Cancer Genet* 2011;204(6):323–7.
16. Chang KC, Wang YC, Hung LY, et al. Monoclonality and cytogenetic abnormalities in hyaline vascular Castleman disease. *Mod Pathol* 2013;27(6):823–31.
17. Leslie C, Shingde M, Kwok F, et al. T-lymphoblastic proliferation and florid multifocal follicular dendritic cell proliferation occurring in hyaline-vascular Castleman disease in a patient with a possible familial predisposition. *J Hematop* 2013;6(4):237–44.
18. Martin CC. Castleman's disease in identical twins. *Virchows Arch A Pathol Anat Histol* 1982;395(1):77–85.
19. Menke DM, Tiemann M, Camoriano JK, et al. Diagnosis of Castleman's disease by identification of an immunophenotypically aberrant population of mantle zone B lymphocytes in paraffin-embedded lymph node biopsies. *Am J Clin Pathol* 1996;105(3):268–76.
20. Aguzzi A, Kranich J, Krautler NJ. Follicular dendritic cells: origin, phenotype, and function in health and disease. *Trends Immunol* 2014;35(3):105–13.
21. Sun X, Chang KC, Abruzzo LV, et al. Epidermal growth factor receptor expression in follicular dendritic cells: a shared feature of follicular dendritic cell sarcoma and Castleman's disease. *Hum Pathol* 2003;34(9):835–40.
22. Vermi WW. Identification of CXCL13 as a new marker for follicular dendritic cell sarcoma. *J Pathol* 2008;216(3):356–64.
23. Post GR. Diagnostic utility of interleukin-6 expression by immunohistochemistry in differentiating Castleman disease subtypes and reactive lymphadenopathies. *Ann Clin Lab Sci* 2016;46(5):474–9.
24. Vinzio S, Ciarloni L, Schlienger JL, et al. Isolated microcytic anemia disclosing a unicentric Castleman disease: the interleukin-6/hepcidin pathway? *Eur J Intern Med* 2008;19(5):367–9.
25. Kishimoto T. IL-6: from its discovery to clinical applications. *Int Immunol* 2010;22(5):347–52.
26. Dossier A, Meignin V, Fieschi C, et al. Human herpesvirus 8-related Castleman disease in the absence of HIV infection. *Clin Infect Dis* 2013;56(6):833–42.
27. Suda T, Katano H, Delsol G, et al. HHV-8 infection status of AIDS-unrelated and AIDS-associated multicentric Castleman's disease. *Pathol Int* 2001;51:671–9.
28. Bower M, Newsom-Davis T, Naresh K, et al. Clinical features and outcome in HIV-associated multicentric Castleman's disease. *J Clin Oncol* 2011;29(18):2481–6.
29. Guihot A, Oksenhendler E, Galicier L, et al. Multicentric Castleman disease is associated with polyfunctional effector memory HHV-8-specific CD8 T cells. *Blood* 2008;111(3):1387–95.
30. Uldrick TS, Polizzotto MN, Yarchoan R. Recent advances in Kaposi sarcoma herpesvirus-associated multicentric Castleman disease. *Curr Opin Oncol* 2012;24(5):495–505.
31. Liu AY, Nabel CS, Finkelman BS, et al. Idiopathic multicentric Castleman's disease: a systematic literature review. *Lancet Haematol* 2016;3(4):e163–75.

32. D'Souza AA. The utility of plasma vascular endothelial growth factor levels in the diagnosis and follow-up of patients with POEMS syndrome. *Blood* 2001;118(17):4663–5.
33. Sekiguchi YY. Ambiguous effects of anti-VEGF monoclonal antibody (bevacizumab) for POEMS syndrome. *J Neurol Neurosurg Psychiatry* 2013;84(12):1346–8.
34. Warsame RR. POEMS syndrome: an enigma. *Curr Hematol Malig Rep* 2017;12(2):85–95.
35. Fajgenbaum DC, van Rhee F, Nabel CS. HHV-8-negative, idiopathic multicentric Castleman disease: novel insights into biology, pathogenesis, and therapy. *Blood* 2014;123(19):2924–33.
36. Kojima M, Motoori T, Asano S, et al. Histological diversity of reactive and atypical proliferative lymph node lesions in systemic lupus erythematosus patients. *Pathol Res Pract* 2007;203(6):423–31.
37. Kojima M, Motoori T, Nakamura S. Benign, atypical and malignant lymphoproliferative disorders in rheumatoid arthritis patients. *Biomed Pharmacother* 2006;60(10):663–72.
38. Kawabata H, Kadowaki N, Nishikori M, et al. Clinical features and treatment of multicentric Castleman's disease : a retrospective study of 21 Japanese patients at a single institute. *J Clin Exp Hematop* 2013;53(1):69–77.
39. Kone-Paut I, Hentgen V, Guillaume-Czitrom S, et al. The clinical spectrum of 94 patients carrying a single mutated MEFV allele. *Rheumatology (Oxford)* 2009;48(7):840–2.
40. Van Eyck LL. Mutant ADA2 in vasculopathies. *N Engl J Med* 2014;371(5):478–9.
41. Dai Y, Zhang W, Wen J, et al. A(2B) adenosine receptor-mediated induction of IL-6 promotes CKD. *J Am Soc Nephrol* 2011;22(5):890–901.
42. Stone K, Woods E, Szmania SM, et al. Interleukin-6 receptor polymorphism is prevalent in HIV-negative Castleman disease and is associated with increased soluble interleukin-6 receptor levels. *PLoS One* 2013;8(1):e54610.
43. Al-Maghrabi J, Kamel-Reid S, Bailey D. Immunoglobulin and T-cell receptor gene rearrangement in Castleman's disease: molecular genetic analysis. *Histopathology* 2006;48(3):233–8.
44. Nakamura H, Nakaseko C, Ishii A, et al. Chromosomal abnormalities in Castleman's disease with high levels of serum interleukin-6. *Rinsho Ketsueki* 1993;34(2):212–7 [in Japanese].
45. Barozzi P, Luppi M, Masini L, et al. Lymphotropic herpes virus (EBV, HHV-6, HHV-8) DNA sequences in HIV negative Castleman's disease. *Clin Mol Pathol* 1996;49(4):M232–5.
46. Bowne WB, Lewis JJ, Filippa DA, et al. The management of unicentric and multicentric Castleman's disease: a report of 16 cases and a review of the literature. *Cancer* 1999;85(3):706–17.
47. Jones EL, Crocker J, Gregory J, et al. Angiofollicular lymph node hyperplasia (Castleman's disease): an immunohistochemical and enzyme-histochemical study of the hyaline-vascular form of lesion. *J Pathol* 1984;144(2):131–47.
48. Murray PG, Deacon E, Young LS, et al. Localization of Epstein-Barr virus in Castleman's disease by in situ hybridization and immunohistochemistry. *Hematol Pathol* 1995;9(1):17–26.
49. Yuan XG, Chen FF, Zhu YM, et al. High prevalence of hepatitis B virus infection in HIV-negative Castleman's disease. *Ann Hematol* 2012;91(6):857–61.
50. Lai YM, Li M, Liu CL, et al. Expression of interleukin-6 and its clinicopathological significance in Castleman's disease. *Zhonghua Xue Ye Xue Za Zhi* 2013;34(5):404–8 [in Chinese].

51. Leger-Ravet MB, Peuchmaur M, Devergne O, et al. Interleukin-6 gene expression in Castleman's disease. *Blood* 1991;78(11):2923–30.
52. Yoshizaki K, Matsuda T, Nishimoto N, et al. Pathogenic significance of interleukin-6 (IL-6/BSF-2) in Castleman's disease. *Blood* 1989;74(4):1360–7.
53. Yu L, Tu M, Cortes J, et al. Clinical and pathological characteristics of HIV- and HHV-8–negative Castleman disease. *Blood* 2017;129(12):1658–68.
54. van Rhee F, Stone K, Szmania S, et al. Castleman disease in the 21st century: an update on diagnosis, assessment, and therapy. *Clin Adv Hematol Oncol* 2010; 8(7):486–98.
55. Alonzi T, Gorgoni B, Screpanti I, et al. Interleukin-6 and CAAT/enhancer binding protein beta-deficient mice act as tools to dissect the IL-6 signalling pathway and IL-6 regulation. *Immunobiology* 1997;198(1–3):144–56.
56. Brandt SJ, Bodine DM, Dunbar CE, et al. Dysregulated interleukin 6 expression produces a syndrome resembling Castleman's disease in mice. *J Clin Invest* 1990;86(2):592–9.
57. van Gameren MM, Willemse PH, Mulder NH, et al. Effects of recombinant human interleukin-6 in cancer patients: a phase I-II study. *Blood* 1994;84(5):1434–41.
58. van Rhee F, Wong RS, Munshi N, et al. Siltuximab for multicentric Castleman's disease: a randomised, double-blind, placebo-controlled trial. *Lancet Oncol* 2014;15(9):966–74.
59. Casper C, Chaturvedi S, Munshi N, et al. Analysis of inflammatory and anemia-related biomarkers in a randomized, double-blind, placebo-controlled study of siltuximab (anti-IL6 monoclonal antibody) in patients with multicentric Castleman disease. *Clin Cancer Res* 2015;21(19):4294–304.
60. Iwaki N, Gion Y, Kondo E, et al. Elevated serum interferon γ -induced protein 10 kDa is associated with TAFRO syndrome. *Sci Rep* 2017;7:42316.
61. Fajgenbaum D, Rosenbach M, van Rhee F, et al. Eruptive cherry hemangiomatosis associated with multicentric Castleman disease: a case report and diagnostic clue. *JAMA Dermatol* 2013;149(2):204–8.
62. El-Osta H, Janku F, Kurzrock R. Successful treatment of Castleman's disease with interleukin-1 receptor antagonist (anakinra). *Mol Cancer Ther* 2010;9(6):1485–8.
63. Galeotti C, Tran TA, Franchi-Abella S, et al. IL-1RA agonist (anakinra) in the treatment of multifocal Castleman disease: case report. *J Pediatr Hematol Oncol* 2008;30(12):920–4.