Castleman Disease

51

Luke Chen and David C. Fajgenbaum

Overview

- There are at least 4 clinically distinct subtypes of Castleman disease: unicentric Castleman disease (UCD), human herpes virus (HHV) 8-associated multicentric Castleman disease (typically associated with HIV), POEMS-associated multicentric Castleman disease, and HHV-8-negative/idiopathic multicentric Castleman disease (iMCD).
- iMCD is often further subdivided into iMCD-TAFRO and iMCD-Not Otherwise Specified (NOS). TAFRO is an acronym for: thrombocytopenia, anasarca, fever, reticulin fibrosis, renal dysfunction, and organomegaly. iMCD-NOS patients tend to have thrombocytosis, plasmacytosis, hypergammaglobulinemia, and a less severe clinical course than iMCD-TAFRO.
- Histopathological features should not be the basis upon which UCD is differentiated from MCD. Rather, the distinction between UCD and MCD should be made by imaging alone.
- Historically, Castleman disease was categorized by the histopathologic appearance of lymph nodes but this provides limited clinical utility.
- First-line treatment of UCD always includes surgical resection, when possible. Complete surgical resection of the involved lymph node(s) is almost always curative.
- Highly active antiretroviral therapy (HAART) and rituximab are quite effective for HHV-8 associated MCD.
- Biologic therapies targeting interleukin-6 are first-line therapies for the treatment of iMCD.

L. Chen (✉)
Division of Hematology, The University of British Columbia, Vancouver, BC, Canada
e-mail: lchen2@bccancer.bc.ca

D. C. Fajgenbaum
Center for Cytokine Storm Treatment and Laboratory & Division of Translational Medicine and Human Genetics, Department of Medicine, Perelman School of Medicine, University of Pennsylvania, Philadelphia, PA, USA
e-mail: davidfa@pennmedicine.upenn.edu

Pearl *Castleman disease describes a group of diseases that should first be divided into unicentric Castleman disease and multicentric Castleman disease.*

Comment: Unicentric Castleman disease involves one or more lymph nodes in one region, generally forming a sizeable mass. For resectable unicentric Castleman disease, complete surgical resection is typically curative. For unresectable unicentric Castleman disease, debulking with embolization or immunotherapy such as rituximab or other treatments for MCD may facilitate safer surgical resection. Treatments for multicentric Castleman disease are tailored based on the etiology/subtype and disease severity. There are occasional patients with a "regional" distribution of lymph nodes that are not easily classifiable as either UCD or MCD. Evidence based consensus diagnostic criteria exist for UCD and iMCD. (cite: https://pubmed.ncbi.nlm.nih.gov/33284946/ and https://pubmed.ncbi.nlm.nih.gov/28087540/)

Myth *Multicentric Castleman disease does not occur in pediatrics.*

Reality: All forms of Castleman disease can occur at any age. The average age of patients at diagnosis is in the 40s, but that reflects the average of a range of patients diagnosed from 1 to 70 years old (Liu et al. 2016).

Pearl *The Castleman Disease Collaborative Network (CDCN) is an excellent resource for physicians, researchers, and patients.*

Comment: The CDCN provides up-to-date information about the disease at www.CDCN.org, an online forum for physicians to communicate with experts about the disease, annual meetings for physicians and patients, and opportunities for patients to contribute their medical data to research through the ACCELERATE Registry (www.CDCN.org/ACCELERATE) or to contribute blood samples to research.

Pearl *The etiology of iMCD is still unknown but it is probably not triggered by an acute viral infection.*

© The Author(s), under exclusive license to Springer Nature Switzerland AG 2023

J. H. Stone (ed.), *A Clinician's Pearls & Myths in Rheumatology*, https://doi.org/10.1007/978-3-031-23488-0_51

Comment: Multiple efforts to search for a viral infection as the etiological driver of HHV-8-negative/idiopathic MCD (iMCD) have been unsuccessful (Nabel et al. 2019). A virus may be involved but somatic mutations, germline mutations, or autoimmune mechanisms are more likely to be causative drivers.

Myth *Castleman disease is a benign, indolent condition in all cases.*

Reality: Although UCD is quite benign and indolent, a small portion of UCD patients will go on to develop FDC sarcoma or paraneoplastic pemphigus with bronchiolitis obliterans organizing pneumonia, which is life threatening. Further, a large proportion of HHV-8-associated MCD patients died before the advent of highly active antiretroviral therapy (HAART) and rituximab. HAART and rituximab are quite effective for HHV-8 associated MCD and have thus turned this disease into a manageable condition. Though progress has also been made for iMCD and POEMS-MCD, important work remains. Currently, one-quarter to one-third of iMCD patients die within 5 years of diagnosis, and POEMS-MCD patients often have significant morbidity related to the motor polyneuropathy (Dispenzieri et al. 2012; Cohen et al. 2021).

Pearl *Multicentric Castleman disease (MCD) should be divided into HHV-8-associated MCD, which is often found in individuals who are HIV-positive or otherwise immunocompromised; POEMS (polyneuropathy, organomegaly, endocrinopathy, M-protein, skin changes)-associated MCD; and HHV-8 negative or idiopathic multicentric Castleman disease (iMCD).*

Comment: Sub-dividing MCD is critical as the treatment approach and progress varies considerably between subgroups. HHV-8-associated MCD is typically treated with rituximab with the addition of cytotoxic chemotherapy or HIV-directed therapy, if needed. POEMS-associated MCD treatment should be directed at the monoclonal plasma cell population. HHV-8-negative/idiopathic MCD cases who do not have concurrent POEMS syndrome should be treated with first-line anti-IL-6 therapy (Fajgenbaum 2018).

Myth *MCD is uncommon in individuals who are HHV-8-negative or HIV-negative. Thus, if evidence of HHV-8 or HIV is not present in a patient with possible MCD, then it is unlikely the patient has MCD.*

Reality: HIV-negative, HHV-8-negative MCD is actually the most common subtype of MCD. In fact, over 50% of MCD patients are HHV-8-negative and HIV-negative and thus have iMCD (Liu et al. 2016). Therefore, the absence of HHV-8 does not affect the conclusion about whether or not a patient has MCD.

Pearl *There seems to be an increased risk in malignancies among patients with Castleman disease.*

Comment: The relative increase in risk of malignancy is not known, but a study from 2016 suggested that iMCD patients had approximately a threefold increased risk of malignancies. Hematologic malignancies, particularly lymphoma, appear to be overrepresented (Liu et al. 2016). Further investigation and discussion with experts in the community suggests that this risk may be lower in reality because there may have been some misdiagnosed patients included in the analysis.

Myth *HIV infection is a risk factor for all types of Castleman disease.*

Reality: HIV infection, the primary risk factor for HHV-8-associated MCD, is not a risk factor for the other forms of Castleman disease.

Pearl *The iMCD-TAFRO (thrombocytopenia, anasarca, fever, reticulin fibrosis, renal dysfunction, and organomegaly) syndrome is a particularly aggressive clinical subtype of iMCD. The stormy presentation of TAFRO contrasts with that of iMCD-NOS, which tends to have a more chronic, indolent clinical course characterized by more marked lymphadenopathy, thrombocytosis, and hypergammaglobulinemia.*

Comment: TAFRO syndrome was first described in 2010 (Takai et al. 2010). This syndrome is associated with severe organ damage and serositis. Although reticulin fibrosis of the bone marrow is part of the acronym, this feature is only seen in about 30–40% of patients. TAFRO can be associated with iMCD or can occasionally occur in the absence of iMCD. The lymphadenopathy and organomegaly of TAFRO are relatively mild (Fig. 51.1). Moreover, the polyclonal hypergammaglobulinemia typical of iMCD-NOS is often absent in TAFRO. Thus, it can be difficult to make a histological diagnosis of iMCD-TAFRO and a high index of suspicion is needed (Nishimura 2021). iMCD-TAFRO and iMCD (NOS) are contrasted in Table 51.1.

Pearl *Adrenalitis or adrenal necrosis is often an early clue to TAFRO.*

Comment: In patients presenting with adrenalitis or adrenal necrosis, severe inflammation, and serositis/anasarca (Fig. 51.2), TAFRO should be considered. Numerous case reports and case series have noted adrenal abnormalities as an early feature, particularly in younger Asian patients (Chen et al. 2021b; Kurokawa et al. 2020).

Pearl *The eruption of cherry hemangiomas on the skin can be a sign of iMCD diagnosis or relapse of iMCD.*

Comment: iMCD patients can have a rapid appearance (or eruption) of cherry hemangiomas at the time of diagnosis or relapse (Fajgenbaum et al. 2013).

Fig. 51.1 Positron emission tomography image demonstrating small, bilateral (up to 2.9 cm) cervical lymphadenopathy, mild hepatomegaly (24 cm in midclavicular line) with diffuse increased bone marrow and splenic uptake in a patient with iMCD-TAFRO. This image underscores the points that the lymphadenopathy and organomegaly of TAFRO are mild compared to these features in other forms of iMCD (iMCD-NOS). In addition, the polyclonal hypergammaglobulinemia typical of iMCD-NOS is often absent in TAFRO. (Figure courtesy of Dr. Don Wilson)

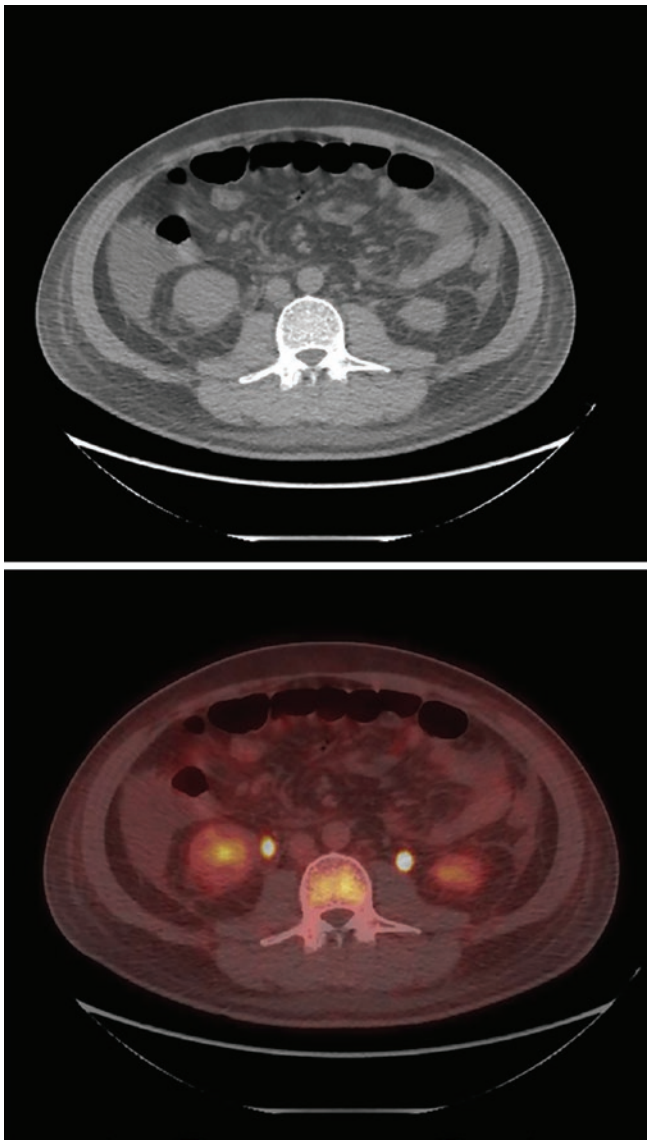

Fig. 51.2 Fused positron emission tomography (PET) and computed tomography (CT) images demonstrating ascites, retroperitoneal stranding, and subcutaneous edema in a patient with iMCD-TAFRO (Figure courtesy of Dr. Don Wilson)

Table 51.1 TAFRO versus iMCD (NOS)

TAFRO	iMCD-NOS
Thrombocytopenia	Thrombocytosis
Anasarca	Mild serositis
Fever	Fever
Reticulin fibrosis	Bone marrow plasmacytosis
Renal dysfunction	Mild renal dysfunction
Organomegaly	Mild organomegaly
Adrenalitis	N/A
Mild lymphadenopathy	Marker lymphadenopathy
Normal immunoglobulin levels	Hypergammaglobulinemia

Myth *Histopathologic subtype should be used to guide iMCD treatment.*

Reality: Insufficient evidence exists to use histopathologic subtype to guide iMCD treatment. Interobserver agreement between pathologists with regard to histopathologic subtype is not reliable. A large portion of iMCD-TAFRO cases are characterized as having hypervascular/hyaline vascular histopathologic subtype. These often respond to IL-6 blockade. In contrast, some less severe iMCD cases that also have hyaline vascular histopathology are less likely to respond to IL-6 blockade (Fajgenbaum 2020). The categorization outlined in Fig. 51.3 is more useful for risk stratification and management than categorizations based on histopathology.

Myth *There are 3 distinct histopathologic variants of Castleman disease: a hyaline vascular form, a plasmacytic form, and a mixed variant.*

1. **Unicentric Castleman disease (UCD)**
2. **Multicentric Castleman disease (MCD)**
   - POEMS-associated MCD
   - HHV-8-associated MCD (some patients HIV+, others HIV-)
   - Idiopathic (iMCD)
     - iMCD-TAFRO (thrombocytopenia, anasarca, fever, reticulin fibrosis, renal insufficiency, and organomegaly)
     - iMCD-NOS (not otherwise specified)

Fig. 51.3 Overview of Castleman disease (adapted from Dispenzieri 2020)

Reality: A spectrum of histopathologic features can be seen in Castleman disease and pathologists are inconsistent in how they separate patients into one histopathological subtype or another. Although hyaline vascular, plasmacytic, and mixed are still terms used to describe the spectrum of features seen in iMCD and all CD patients must demonstrate histopathologic features consistent with CD, the distinctions between these histopathological features are fuzzy and classifications rendered vary widely by pathologist (Fajgenbaum 2020).

Myth *If a patient has hyaline vascular histopathologic subtype, then they almost certainly have unicentric Castleman disease.*

Reality: This is not correct. A large portion of MCD patients demonstrate hyaline vascular histopathological features, which are often referred to as "hypervascular." Histopathological features should not be the basis upon which UCD is differentiated from MCD. Rather, the distinction between UCD and MCD should be made by imaging alone.

Myth *If a patient with multicentric Castleman disease has hyaline vascular histopathological features, then they likely have an indolent form of MCD.*

Reality: While there have been reports of patients with iMCD who have hyaline vascular histopathological features that present with an indolent case, the most severe iMCD-TAFRO cases tend to have histopathological features consistent with a hyaline vascular or hypervascular designation. This highlights the importance of not using histopathological features to infer prognosis and treatment.

Myth *If a patient has plasmacytic histopathologic subtype, then they almost certainly have MCD rather than UCD.*

Reality: This is not correct. A large portion of MCD patients demonstrate "mixed" histopathological features that are difficult to classify unequivocally, and UCD patients can demonstrate plasmacytic histopathologic features (i.e., they are not confined to having hyaline vascular findings). Again, histopathological features should not be the basis on which UCD and MCD are distinguished: the distinction should be made with imaging alone.

Pearl *A histological diagnosis is necessary for diagnosis of iMCD* (Fig. 51.4).

Comment: Although there are occasionally times when treatment must be administered before establishment of the diagnosis, histological review of lymph node tissue is essential to diagnosing iMCD and to excluding mimickers such as lymphoma. In addition to histopathological criteria, patients must also have multicentric lymphadenopathy, clinical features consistent with iMCD, and meet exclusion criteria. The hemophagocytic variant of intravascular B-cell lymphoma and IgG4-related disease (Ponzoni et al. 2018; Chen et al. 2019; Sasaki et al. 2017) are both notable histologic mimickers of iMCD.

Myth *iMCD patients can be asymptomatic.*

Reality: Since patients must demonstrate at least 2 clinical minor criteria and have at least 1 laboratory abnormality to be diagnosed with iMCD (Fajgenbaum et al. 2017), it is not possible to have an iMCD patient who is asymptomatic at presentation. The clinical and laboratory criteria for iMCD are summarized in Table 51.2. The upshot of these criteria is that any patient who fulfills criteria for classification as an iMCD patient would have symptoms of one sort or another that are compatible with iMCD.

Myth *UCD patients are never symptomatic.*

Reality: A small but notable portion of UCD patients present with constitutional symptoms and a smaller portion demonstrate symptoms related to compression of neighboring structures or an iMCD-like inflammatory syndrome. First-line treatment of UCD always includes surgical resection, when possible. If the UCD lesion is unresectable, treatment should be determined based on symptoms. Asymptomatic patients can be followed with a watch-and-wait approach. In contrast, patients with symptoms related to compression by a UCD mass should receive B-cell depletion therapy to shrink the lymph node. Patients with inflammation-related symptoms should receive anti-IL-6 therapy to reduce inflammation (van Rhee 2020).

Myth *All cases of UCD are cured with surgical excision.*

Reality: Complete surgical resection of the involved lymph node(s) is almost always curative when able to be performed and is considered the gold standard approach for the treatment of UCD. For some patients, however, complete lymph node resect is not possible. Rarely, patients who have undergone what appears to have been a complete resection experience either symptom recurrence or lingering symptoms that never really abate (van Rhee 2020).

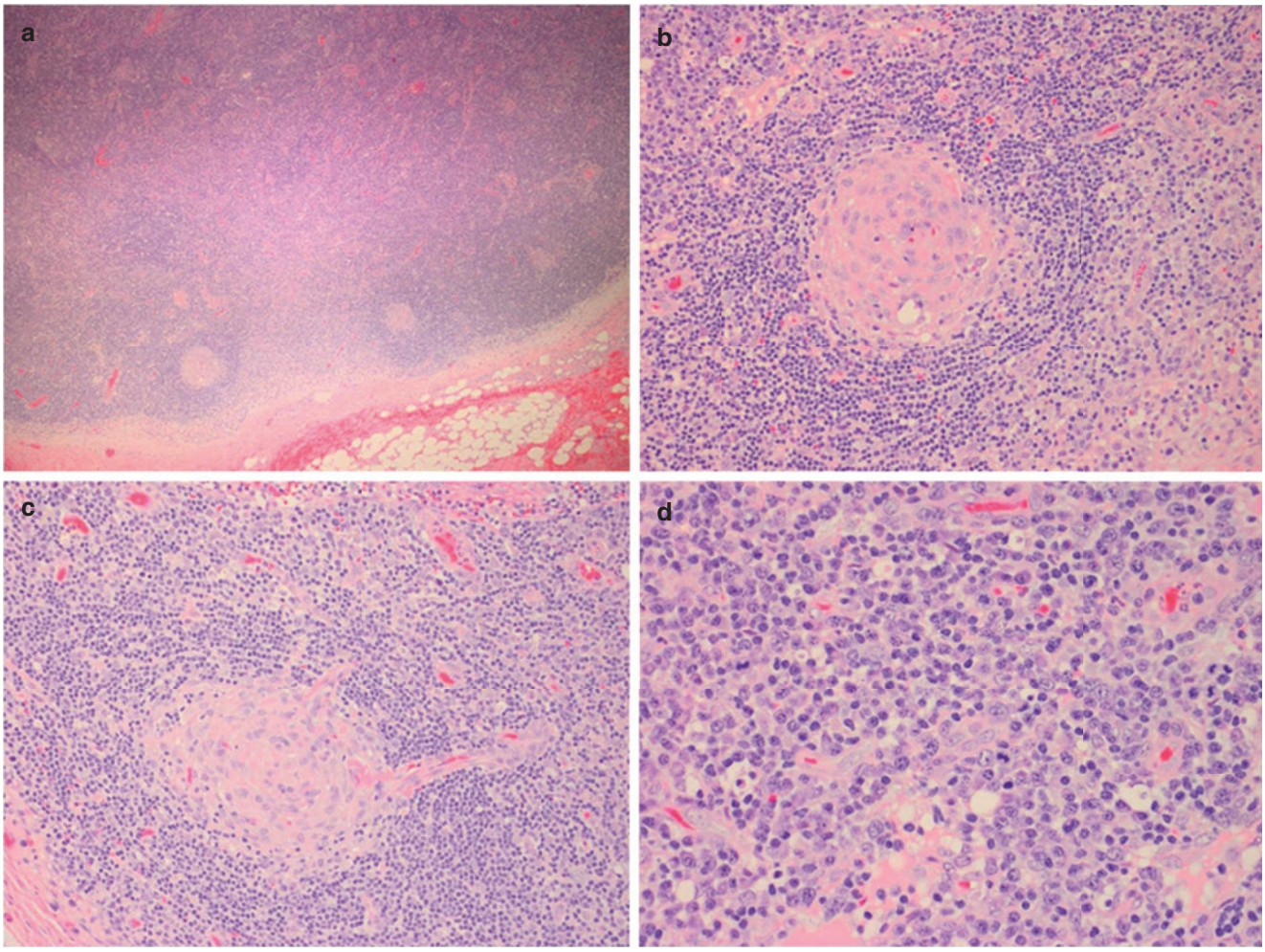

Fig. 51.4 Lymph node histopathology in idiopathic multicentric Castleman disease (iMCD). (**a**) Many regressed germinal centers. (**b**) Prominent follicular dendritic cells. (**c**) Prominent vascularity. (**d**) Marked plasmacytosis (Figure courtesy of Dr. Brian F. Skinnider)

Table 51.2 Clinical and laboratory criteria for iMCD[a]

Clinical:
• Constitutional symptoms: night sweats, fever (>38 °C), weight loss, or fatigue (≥Common Terminology Criteria for Adverse Events lymphoma score for B symptoms)
• Large spleen and/or liver
• Fluid accumulation: edema, anasarca, ascites, or pleural effusion
• Eruptive cherry hemangiomatosis or violaceous papules
• Lymphocytic interstitial pneumonitis
Laboratory:
• Elevated C-reactive protein (CRP) > 10 mg/L or ESR > 15 mm/h
• Anemia (hemoglobin <12.5 g/dL for males, <11.5 g/dL for females)
• Thrombocytopenia (platelets <150 k/μL) or thrombocytosis (platelets >400 k/μL)
• Hypoalbuminemia (albumin <3.5 g/L)
• Renal dysfunction (eGFR <60 mL/min/1.73 m^2) or proteinuria (total protein 150 mg/24 h or 10 mg/100 mL)
• Polyclonal hypergammaglobulinemia (total gamma globulins or IgG > 1700 mg/dL)

[a]*Patients must demonstrate at least 2 clinical minor criteria and have at least 1 laboratory abnormality to be diagnosed with iMCD* (Fajgenbaum et al. 2017)

Pearl *All three forms of MCD are best described as "cytokine storm" disorders.*

Comment: Though only recently defined, cytokine storm describes a group of disorders of immune dysregulation characterized by constitutional symptoms, systemic inflammation, and multiorgan dysfunction that can lead to multiorgan failure if inadequately treated. Improvement in outcomes with immunosuppressive or anti-cytokine therapies, which is observed in all three forms of MCD, supports the concept that these conditions should be included under the umbrella of cytokine storm (Fajgenbaum and June 2020).

Myth *iMCD can be diagnosed concurrently with lupus or lymphoma.*

Reality: In order to diagnose iMCD, a series of tests are required to exclude diseases such as lupus and lymphoma that can mimic iMCD (Fajgenbaum et al. 2017). A full list of important mimickers not to overlook and to exclude is shown in Table 51.3.

Table 51.3 iMCD mimickers not to miss

Infection-related disorders
• HHV-8
• Clinical EBV-lymphoproliferative disorders
• Inflammation and lymphadenopathy caused by infections such as CMV, toxoplasmosis, HIV, tuberculosis
Autoimmune/autoinflammatory diseases
• Systemic lupus erythematosus
• Rheumatoid arthritis
• Adult-onset still disease
• Juvenile idiopathic arthritis
• Autoimmune lymphoproliferative syndrome
Malignant/lymphoproliferative disorders
• Lymphoma
• Plasma cell myeloma
• Primary lymph node plasmacytoma
• FDC sarcoma
• POEMS syndrome (POEMS-associated MCD)

Pearl *Polyclonal hypergammaglobulinemia, an important clue to the diagnosis of some cases of iMCD, is rarely found in the iMCD-TAFRO clinical subtype.*

Comment: Patients with iMCD-NOS often present with an impressive polyclonal hypergammaglobulinemia. In fact, a hypergammaglobulinemia exceeding total immunoglobulins of higher than 17 g/L is a minor criterion for diagnosis of iMCD (Fajgenbaum et al. 2017). This stands in contrast to iMCD-TAFRO, which despite its often highly inflammatory nature and stormy presentation is almost never associated with gamma globulin levels that are any more than mildly elevated.

Any (or all) of the IgG subclasses may be elevated in iMCD-NOS patients. This includes an IgG4 hypergammaglobulinemia, which means that iMCD-NOS associated with an elevated serum IgG4 can mimic IgG4-RD (Zhao et al. 2020). In fact, IgG4-RD is another condition in which all four IgG subclasses can be elevated, meaning that some other basis for distinguishing between these conditions is required. In iMCD-NOS, the C-reactive protein is typically very elevated, these patients tend to respond poorly to steroids, and they do not have extranodal lesions, whereas CRP is typically normal or mildly elevated in IgG4-RD, these patients respond well to steroids and typically have extranodal lesions.

iMCD-NOS can mimic both IgG4-RD and Rosai-Dorfman-Destombes (RDD) disease in that all three rare diseases present with lymphadenopathy, polyclonal hypergammaglobulinemia with elevated serum IgG4, and an abundance of IgG4-positive plasma cells in tissue samples (Chen et al. 2019). Although the relative increase of serum IgG4 is generally higher in IgG4-RD, these diseases and others can present with a polyclonal hypergammaglobulinemia characterized with "beta-gamma bridging." Beta-gamma bridging in these conditions results from the fact that IgG4, like IgA, often runs in the fast gamma region and obliterates the normal depression between the beta and gamma zones on a serum protein electrophoresis (Fig. 51.5).

Pearl *In patients with lymphadenopathy and polyclonal hypergammaglobulinemia with elevated serum IgG4, histology and C-reactive protein can help distinguish iMCD from Rosai-Dorfman-Destombes disease and IgG4-related disease.*

Comment: The most important means of distinguishing between these three entities is histology. Rosai-Dorfman disease is a rare histiocyte disorder that often presents with large cervical lymph nodes characterized by histiocytic infiltration, histiocytocytes that are marked by hypochromatic nuclei and pale cytoplasm positive, positive staining for CD68 and S100, and the striking finding of emperipolesis of lymphocytes or plasma cells within the histiocytes (Chen et al. 2021c).

IgG4-RD is sometimes difficult to distinguish clearly from iMCD on the basis of histopathology, but other clues to this diagnosis can be found in its clinical, radiological, and serological features (Wallace 2020). For example, whereas the C-reactive protein (CRP) is typically >30 mg/L in iMCD and can be variably elevated in Rosai-Dorfman disease, patients with IgG4-RD typically do not have markedly elevated CRP values (Zhao et al. 2021).

Myth *Interleukin-6 is markedly elevated in all cases of iMCD.*

Reality: Although IL-6 drives much of the pathophysiology of iMCD, such as the lymphadenopathy, anemia, and polyclonal hypergammaglobulinemia (Brandt et al. 1990) and IL-6 blockade alleviates many of these problems, serum IL-6 levels are often only modestly elevated in patients with iMCD. IL-6 values in iMCD are typically in the 10–150 pg/mL range (normal <7 pg/mL in most laboratories)(England et al. 2021). In contrast, serum IL-6 levels are often several hundred pg/mL in sepsis and well over 1000 pg/mL in the chimeric antigen T-cell receptor cytokine release syndrome (CAR-T cell CRS).

The relatively modest elevation of the central cytokine implicated in iMCD appears paradoxical, but may be related to the complex trans-signaling system used by tissues that do not express membrane-bound IL-6 receptor. Trans-signaling relies upon soluble interleukin-6 receptor (sIL-6R) to overcome the inhibitory effect of soluble glycoprotein receptor 130 and can thus occur in the presence of relatively low levels of serum IL-6 as long as sufficient levels of soluble IL-6R are present (Chen et al. 2021a). Alternatively, there may be other cytokines or chemokines that are driving iMCD in patients with normal IL-6 levels and/or lacking a response to anti-IL-6 therapy (Pierson et al. 2018).

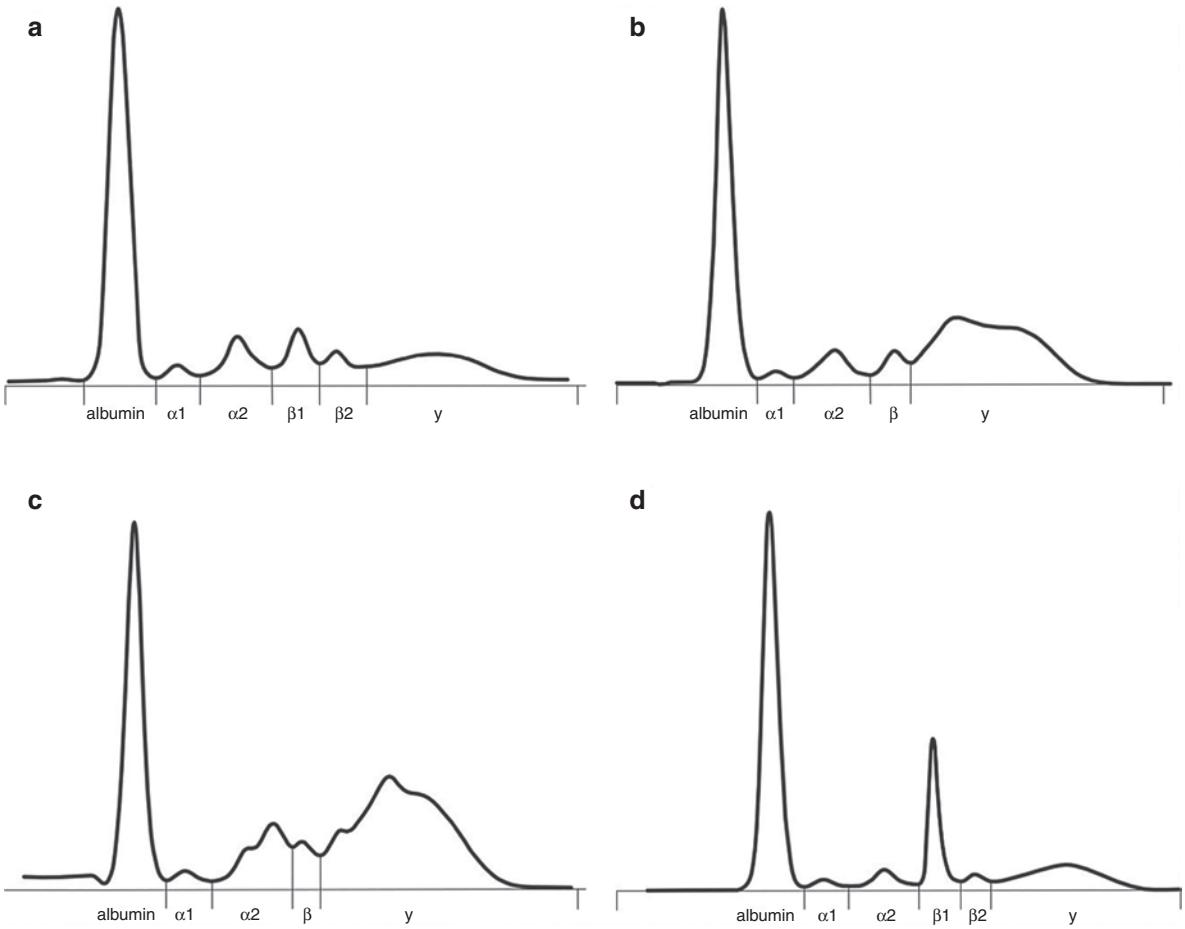

Fig. 51.5 Serum protein electrophoresis studies: normal and in several disease states. Serum protein electrophoresis (SPEP) involves dispensing serum into an agarose gel or into a capillary electrophoresis system, to which an electric field is applied. Proteins in the sample migrate through the medium in response to this electric field with the rate of migration determined by both the protein's size and charge, creating a characteristic pattern of protein migration. (**a**) Normal pattern. Panel **a** shows a normal distribution of proteins on SPEP. Albumin, the largest peak, lies closest to the positive electrode, followed by characteristic peaks termed alpha-1, alpha-2, beta-1, beta-2, and gamma. A monoclonal protein will produce a narrow spike-like peak in a focal region, most commonly within the gamma region (thus the term "monoclonal gammopathy"). Monoclonal spikes can also occur in the beta regions. (**b**) IgG4-related disease (IgG4-RD). Polyclonal hypergammaglobulinemia in IgG4-RD. This patient with IgG4-RD has a broad polyclonal increase in gamma globulins that obscures the typical depression between the beta and gamma regions, a pattern known as "beta-gamma bridging." In this case, the pattern is caused by polyclonal IgG4, but a polyclonal increase in IgA, often seen in liver disease, may cause a similar pattern. In this case, the total IgG is 39 g/L (normal 7–16 g/L) and the IgG4 is nine times the upper limit of normal: 12.4 g/L (normal 0.05–1.25 g/L). With IgG4-RD, the serum IgG4 is characteristically elevated out of proportion to the other immunoglobulins, even if all for gamma globulin components are increased. The serum IgA is this case is slightly low, 0.65 g/L (normal 0.7–4.0 g/L). (**c**) Idiopathic multicentric Castleman disease (iMCD). Polyclonal hypergammaglobulinemia in a patient with iMCD-NOS. There is a polyclonal increase in total IgG 52 g/L (normal 7–16 g/L) caused primarily by an elevated serum IgG4 component. The serum IgG4 is 10.2 g/L (normal 0.05–1.25 g/L) and beta-gamma bridging is apparent. (**d**) Schnitzler syndrome. Monoclonal paraprotein in a patient with Schnitzler syndrome, who has a monoclonal 10 g/L IgM kappa band in the beta region in the context of urticarial vasculitis. Soluble IgM exists as a pentamer and often migrates in the beta1 or beta2 region of the protein electrophoresis, causing the monoclonal spike observed here (Figure courtesy of Dr. Eric J Zhao)

Pearl *IL-6 inhibitors with or without glucocorticoids form the backbone of systemic therapy for iMCD.*

Comment: In a phase II randomized controlled trial examining the anti-IL-6 monoclonal antibody siltuximab (11 mg/kg IV every 3 weeks) compared to placebo, 34% of patients achieved the primary endpoint of a durable symptomatic and lymph node response. Approximately 60% of patients given siltuximab had a durable symptomatic response and remained on study drug through the end of the trial, suggesting it was providing a clinical benefit. Tocilizumab, a monoclonal antibody directed against the IL-6 receptor, was evaluated in a prospective single-arm prospective study of 35 patients in Japan (van Rhee et al. 2018). A similar proportion of clinical and biochemical improvement was observed.

Myth *Failure to respond to IL-6 blockade means that the patient probably does not have iMCD.*

Reality: This is far from being true, unfortunately. Only one-third to one-half of all patients respond to IL-6 blockade (van Rhee et al. 2014). A large proportion of patients do not and their diagnosis should not be overturned due to lack of response.

Pearl *For refractory or relapsed iMCD, multi-agent cytotoxic therapy is often employed. Other immunomodulatory therapies may also be beneficial.*

Comment: In an iMCD patient with severe iMCD, who is not responding to first-line anti-IL-6 therapy and experiencing disease progression, multi-agent chemotherapy should be given. More recently, research has uncovered that mTOR upregulation is an important feature of IL-6 blockade refractory iMCD (Arenas et al. 2020; Pai et al. 2020). Sirolimus targets the mTOR pathway and has been beneficial in case reports (Fajgenbaum et al. 2019), as has cyclosporine. A clinical trial (NCT03933904) is currently open using sirolimus for anti-IL-6-refractory patients.

Myth *Failure of one agent means failure of that class of agents.*

Reality: Though it is rare and data are limited, patients who fail siltuximab may respond to tocilizumab and vice versa (Chen et al. 2021b). Clinical and biological responses to anti-IL-6 therapies tend to occur rapidly, within a few days or weeks. So if treatment with one IL-6-directed therapy is not working, it should be evident within several weeks.

Myth *Chemotherapy should be used first-line as the treatment for iMCD.*

Reality: Chemotherapy should only be used for severe iMCD patients whose disease is progressing despite IL-6 blockade (van Rhee et al. 2018).

Myth *Radiation should be used for the treatment of iMCD.*

Comment: Radiation is not recommended for any patients with iMCD (van Rhee et al. 2018).

Pearl *Patients with more abnormal laboratory values tend to have an increased likelihood of response to anti-IL-6 therapy.*

Comment: Although all iMCD patients may benefit from IL-6 blockade and should receive it as part of their first-line therapy, the greater the abnormality of laboratory values the higher the likelihood of response to anti-IL-6 therapy (Morra et al. 2019).

Pearl *CRP, hemoglobin, and albumin are important biochemical markers of response to therapy. In contrast, IL-6 is spuriously elevated in patients on IL-6 blockade.*

Comment: CRP, produced by hepatocytes in response to IL-6, falls rapidly within days following IL-6 blockade. Hemoglobin and albumin are also good markers of response to IL-6-directed therapy. However, serum IL-6 levels are spuriously elevated in patients receiving siltuximab or tocilizumab and will remain so for 18–24 months after the last dose. Therefore, IL-6 levels should not be measured or tracked for 1–2 years after a dose of siltuximab or tocilizumab is administered.

References

Arenas DJ, Floess K, Kobrin D, Pai RL, Srkalovic MB, Tamakloe MA, Rasheed R, Ziglar J, Khor J, Parente SAT, Pierson SK, Martinez D, Wertheim GB, Kambayashi T, Baur J, Teachey DT, Fajgenbaum DC. Increased mTOR activation in idiopathic multicentric Castleman disease. Blood. 2020;135:1673–84.

Brandt SJ, Bodine DM, Dunbar CE, Nienhuis AW. Dysregulated interleukin 6 expression produces a syndrome resembling Castleman's disease in mice. J Clin Invest. 1990;86:592–9.

Chen LYC, Mattman A, Seidman MA, Carruthers MN. IgG4-related disease: what a hematologist needs to know. Haematologica. 2019;104:444–55.

Chen LYC, Biggs CM, Jamal S, Stukas S, Wellington CL, Sekhon MS. Soluble interleukin-6 receptor in the COVID-19 cytokine storm syndrome. Cell Rep Med. 2021a;2(5):100269.

Chen LYC, Skinnider BF, Wilson D, Fajgenbaum DC. Adrenalitis and anasarca in idiopathic multicentric Castleman's disease. Lancet. 2021b;397:1749.

Chen LYC, Slack GW, Carruthers MN. IgG4-related disease and Rosai-Dorfman-Destombes disease. Lancet. 2021c;398(10307):1213–4.

Cohen AB, Swaminathan A, Wang X, Zamora S, Repucci MA, Kelly J, Hannan MD, Sepler D, Sridharma S, Orlando A, Leybovich B, Fajgenbaum D. Clinical characteristics, treatment patterns, and overall survival of real-world patients with idiopathic multicentric Castleman disease. J Clin Oncol. 2021;39:7048.

Dispenzieri A, Fajgenbaum DC. Overview of Castleman disease. Blood. 2020;135:1353–64.

Dispenzieri A, Armitage JO, Loe MJ, Geyer SM, Allred J, Camoriano JK, Menke DM, Weisenburger DD, Ristow K, Dogan A, Habermann TM. The clinical spectrum of Castleman's disease. Am J Hematol. 2012;87:997–1002.

England JT, Abdulla A, Biggs CM, Lee AYY, Hay KA, Hoiland RL, Wellington CL, Sekhon M, Jamal S, Shojania K, Chen LYC. Weathering the COVID-19 storm: lessons from hematologic cytokine syndromes. Blood Rev. 2021;45:100707.

Fajgenbaum DC. Novel insights and therapeutic approaches in idiopathic multicentric Castleman disease. Blood. 2018;132:2323–30.

Fajgenbaum DC, June CH. Cytokine storm. N Engl J Med. 2020;383:2255–73.

Fajgenbaum DC, Rosenbach M, van Rhee F, Nasir A, Reutter J. Eruptive cherry hemangiomatosis associated with multicentric Castleman disease: a case report and diagnostic clue. JAMA Dermatol. 2013;149:204–8.

Fajgenbaum DC, Uldrick TS, Bagg A, Frank D, WU D, Srkalovic G, Simpson D, Liu AY, Menke D, Chandrakasan S, Lechowicz MJ, Wong RS, Pierson S, Paessler M, Rossi JF, Ide M, Ruth J, Croglio M, Suarez A, Krymskaya V, Chadburn A, Colleoni G, Nasta S, Jayanthan R, Nabel CS, Casper C, Dispenzieri A, Fossa A, Kelleher D, Kurzrock R, Voorhees P, Dogan A, Yoshizaki K, van Rhee F, Oksenhendler E, Jaffe ES, Elenitoba-Johnson KS, Lim MS. International, evidence-based consensus diagnostic criteria for HHV-8-negative/idiopathic multicentric Castleman disease. Blood. 2017;129:1646–57.

Fajgenbaum DC, Langan RA, Japp AS, Partridge HL, Pierson SK, Singh A, Arenas DJ, Ruth JR, Nabel CS, Stone K, Okumura M, Schwarer A, JOSE FF, Hamerschlak N, Wertheim GB, Jordan MB, Cohen AD, Krymskaya V, Rubenstein A, Betts MR, Kambayashi T, van Rhee F, Uldrick TS. Identifying and targeting pathogenic PI3K/AKT/mTOR signaling in IL-6-blockade-refractory idiopathic multicentric Castleman disease. J Clin Invest. 2019;129:4451–63.

Fajgenbaum DC, Wu D, Goodman A, Wong R, Chadburn A, Nasta S, Srkalovic G, Mukherjee S, Leitch H, Jayanthan R, Ferrero S, Sato Y, Schey S, Dispenzieri A, Oksenhendler E, Zinzani PL, Lechowicz MJ, Hoffmann C, Pemmaraju N, Bagg A, Fossa A, Lim MS, van Rhee F, Castleman Disease Collaborative Network Scientific Advisory Board diagnostic criteria international working group and treatment guidelines international working group. Insufficient evidence exists to use histopathologic subtype to guide treatment of idiopathic multicentric Castleman disease. Am J Hematol. 2020;95:1553–61.

Kurokawa R, Gonoi W, Yokota H, Isshiki S, Ohira K, Mizuno H, Kiguchi T, Inui S, Kurokawa M, Kato S, Matsuki M, Takeda T, Yokoyama K, Ota Y, Nakai Y, Maeda E, Mori H, Abe O. Computed tomography findings of early-stage TAFRO syndrome and associated adrenal abnormalities. Eur Radiol. 2020;30:5588–98.

Liu AY, Nabel CS, Finkelman BS, Ruth JR, Kurzrock R, van Rhee F, Krymskaya VP, Kelleher D, Rubenstein AH, Fajgenbaum DC. Idiopathic multicentric Castleman's disease: a systematic literature review. Lancet Haematol. 2016;3:e163–75.

Morra DE, Pierson SK, Shilling D, Nemat S, Appiani C, Guilfoyle M, Tendler C, van Rhee F, Fajgenbaum DC. Predictors of response to anti-IL6 monoclonal antibody therapy (siltuximab) in idiopathic multicentric Castleman disease: secondary analyses of phase II clinical trial data. Br J Haematol. 2019;184:232–41.

Nabel CS, Sameroff S, Shilling D, Alapat D, Ruth JR, Kawano M, Sato Y, Stone K, Spetalen S, Valdivieso F, Feldman MD, Chadburn A, Fosså A, van Rhee F, Lipkin WI, Fajgenbaum DC. Virome capture sequencing does not identify active viral infection in unicentric and idiopathic multicentric Castleman disease. PLoS One. 2019;14:e0218660.

Nishimura Y, Fajgenbaum DC, Pierson SK, Iwaki N, Nishikori A, Kawano M, Nakamura N, Izutsu K, Takeuchi K, Nishimura MF, Maeda Y, Otsuka F, Yoshizaki K, Oksenhendler E, van Rhee F, Sato Y. Validated international definition of the thrombocytopenia, anasarca, fever, reticulin fibrosis, renal insufficiency, and organomegaly clinical subtype (TAFRO) of idiopathic multicentric Castleman disease. Am J Hematol. 2021;96(10):1241–52.

Pai R-AL, Japp AS, Gonzalez M, Rasheed RF, Okumura M, Arenas D, Pierson SK, Powers V, Layman AAK, Kao C, Hakonarson H, van Rhee F, Betts MR, Kambayashi T, Fajgenbaum DC. Type I IFN response associated with mTOR activation in the TAFRO subtype of idiopathic multicentric Castleman disease. JCI Insight. 2020;5(9):e135031.

Pierson SK, Stonestrom AJ, Shilling D, Ruth J, Nabel CS, Singh A, Ren Y, Stone K, LI H, van Rhee F, Fajgenbaum DC. Plasma proteomics identifies a 'chemokine storm' in idiopathic multicentric Castleman disease. Am J Hematol. 2018;93:902–12.

Ponzoni M, Campo E, Nakamura S. Intravascular large B-cell lymphoma: a chameleon with multiple faces and many masks. Blood. 2018;132:1561–7.

Sasaki T, Akiyama M, Kaneko Y, Mori T, Yasuoka H, Suzuki K, Yamaoka K, Okamoto S, Takeuchi T. Distinct features distinguishing IgG4-related disease from multicentric Castleman's disease. RMD Open. 2017;3:e000432.

Takai K, Nikkuni K, Shibuya H, Hashidate H. Thrombocytopenia with mild bone marrow fibrosis accompanied by fever, pleural effusion, ascites and hepatosplenomegaly. Rinsho Ketsueki. 2010;51:320–5.

van Rhee F, Wong RS, Munshi N, Rossi JF, Ke XY, Fossa A, Simpson D, Capra M, Liu T, Hsieh RK, Goh YT, Zhu J, Cho SG, Ren H, Cavet J, Bandekar R, Rothman M, Puchalski TA, Reddy M, van de Velde H, Vermeulen J, Casper C. Siltuximab for multicentric Castleman's disease: a randomised, double-blind, placebo-controlled trial. Lancet Oncol. 2014;15:966–74.

van Rhee F, Voorhees P, Dispenzieri A, Fosså A, Srkalovic G, IDE M, Munshi N, Schey S, Streetly M, Pierson SK, Partridge HL, Mukherjee S, Shilling D, Stone K, Greenway A, Ruth J, Lechowicz MJ, Chandrakasan S, Jayanthan R, Jaffe ES, Leitch H, Pemmaraju N, Chadburn A, Lim MS, Elenitoba-Johnson KS, Krymskaya V, Goodman A, Hoffmann C, Zinzani PL, Ferrero S, Terriou L, Sato Y, Simpson D, Wong R, Rossi J-F, Nasta S, Yoshizaki K, Kurzrock R, Uldrick TS, Casper C, Oksenhendler E, Fajgenbaum DC. International, evidence-based consensus treatment guidelines for idiopathic multicentric Castleman disease. Blood. 2018;132:2115–24.

van Rhee F, Oksenhendler E, Srkalovic G, Voorhees P, LIM M, Dispenzieri A, Ide M, Parente S, Schey S, Streetly M, Wong R, Wu D, Maillard I, Brandstadter J, Munshi N, Bowne W, Elenitoba-Johnson KS, Fössa A, Lechowicz MJ, Chandrakasan S, Pierson SK, Greenway A, Nasta S, Yoshizaki K, Kurzrock R, Uldrick TS, Casper C, Chadburn A, Fajgenbaum DC, Board, O. B. O. T. C. D. C. N. S. A. International evidence-based consensus diagnostic and treatment guidelines for unicentric Castleman disease. Blood Adv. 2020;4:6039–50.

Wallace ZS, Naden RP, Chari S, Choi HK, Della-Torre E, Dicaire JF, Hart PA, Inoue D, Kawano M, Khosroshahi A, Lanzillotta M, Okazaki K, Perugino CA, Sharma A, Saeki T, Schleinitz N, Takahashi N, Umehara H, Zen Y, Stone JH, Members OF THE, A. C. R. E. I. R. D. C. C. W. G. The 2019 American College of Rheumatology/European League against rheumatism classification criteria for IgG4-related disease. Ann Rheum Dis. 2020;79:77–87.

Zhao EJ, Carruthers MN, Li CH, Mattman A, Chen LYC. Conditions associated with polyclonal hypergammaglobulinemia in the IgG4-related disease era: a retrospective study from a hematology tertiary care center. Haematologica. 2020;105:e121–3.

Zhao EJ, Cheng CV, Mattman A, Chen LYC. Polyclonal hypergammaglobulinaemia: assessment, clinical interpretation, and management. Lancet Haematol. 2021;8:e365–75.