

How We Manage Idiopathic Multicentric Castleman Disease

Joshua D. Brandstadter, MD, PhD,¹ and David C. Fajgenbaum, MD, MBA²

¹Division of Hematology/Oncology, Department of Medicine, Perelman School of Medicine, University of Pennsylvania, Philadelphia, Pennsylvania

²Center for Cytokine Storm Treatment & Laboratory, Division of Translational Medicine and Human Genetics, Perelman School of Medicine, University of Pennsylvania, Philadelphia, Pennsylvania

Overview

- We recommend first-line treatment with anti-interleukin 6 (anti-IL-6) for all patients with idiopathic multicentric Castleman disease.
- We recommend enrollment of all patients with the Castleman Disease Collaborative Network.
- For patients with severe disease, we recommend the accelerated weekly dosing of anti-IL-6 therapy in combination with high-dose corticosteroids with close monitoring and consideration of cytotoxic chemotherapy.
- In mild or moderate cases, we follow standard anti-IL-6 dosing schedules and consider clinical trial enrollment, rituximab, or other immune modulators for nonresponders.

Introduction

Multicentric Castleman disease (MCD), which comprises a heterogeneous group of atypical lymphoproliferative disorders, can pose unique challenges to both patients and clinicians that result in diagnostic confusion and treatment delays. Affecting roughly 1600 patients annually in the United States, MCD is difficult to diagnose and life-threatening, with a historical 5-year overall survival rate of 55% to 77%.¹⁻⁶ Patients demonstrate a range of signs and symptoms, including multicentric lymphadenopathy, an inflammatory syndrome, and fluid accumulation. In addition, multiorgan system dysfunction may develop as a consequence of the cytokine storm. Cytokines whose serum levels are highly elevated often include interleukin 6 (IL-6).^{7,8}

Approximately half of all cases of MCD are caused by uncontrolled infection with human herpesvirus 8 (HHV8-associated MCD) or a monoclonal plasma cell population associated with POEMS (polyneuropathy, organomegaly, endocrinopathy, M proteins, and skin changes) syndrome (POEMS syndrome-associated MCD); the remaining

cases are idiopathic (iMCD). Cases of iMCD are further divided into 3 clinical subtypes. TAFRO syndrome (iMCD-TAFRO) involves severe thrombocytopenia (T), anasarca (A), fever (F), bone marrow reticulin fibrosis or renal dysfunction (R), and organomegaly (O).⁹ iMCD with idiopathic plasmacytic lymphadenopathy (iMCD-IPL) is defined by thrombocytosis, hypergammaglobulinemia, and a milder clinical course. In addition, the subtype of iMCD not otherwise specified (iMCD-NOS) includes cases that do not meet the criteria for iMCD-TAFRO or iMCD-IPL.⁹ This case-based discussion serves as a practical guide to establish a diagnosis of iMCD and provide appropriate treatment. Importantly, we strongly recommend consultation with the Castleman Disease Collaborative Network (CDCN), which can be facilitated through www.CDCN.org or by emailing info@castlemannetwork.org.¹⁰ Consultation is critical to ensure that patients have timely access to clinicians experienced in the treatment of CD and can connect with the larger community, and to support research greatly needed to improve diagnostic tools and therapies for this poorly understood disease. The treatment of HHV8-associated MCD and POEMS-associated MCD is reviewed elsewhere.^{11,12}

How We Make the Diagnosis

The publication of evidence-based consensus diagnostic criteria for iMCD has successfully standardized previously disparate paths to establishing the diagnosis.³ The diagnostic criteria are as follows: (1) enlarged lymph nodes in multiple stations; (2) morphologic changes consistent with CD in an excised lymph node that is negative for HHV8 by immunohistochemistry; (3) the presence of at least 2 minor criteria (including at least 1 laboratory abnormality), which include clinical and laboratory abnormalities consistent with iMCD and an inflammatory syndrome; and (4) the exclusion of infectious, autoimmune, and malignant disorders that can mimic iMCD (Figure 1). Characteristic histopathologic features may include a constellation of regressed

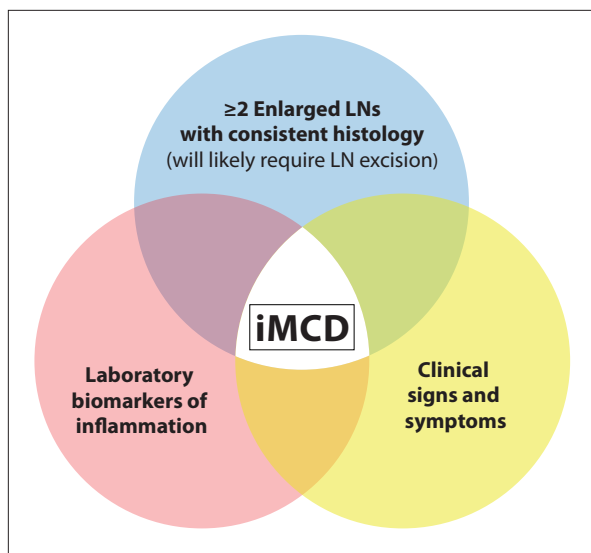


Figure 1. The diagnosis of iMCD requires a clinical assessment to identify symptoms and signs of inflammation, laboratory blood test results suggesting systemic inflammation, imaging showing multifocal lymphadenopathy, and an excisional LN biopsy specimen with iMCD-consistent histology. The pathologic findings of iMCD are by themselves nonspecific, and LNs with Castleman-like histologic features can be seen in infectious, autoimmune/inflammatory, or malignant conditions. For this reason, it is important to exclude alternative etiologies. Further, other subtypes of Castleman disease—such as unicentric Castleman disease and oligocentric Castleman disease, in which 2 to 3 adjacent LN stations may be enlarged but signs and symptoms of systemic inflammation are lacking—should be excluded.

iMCD, idiopathic multicentric Castleman disease; LN, lymph node.

or hyperplastic germinal centers, follicular dendritic cell prominence, hypervascularization, and polytypic plasmacytosis. The minor criteria include an elevated erythrocyte sedimentation rate (ESR) or C-reactive protein (CRP) level, anemia, thrombocytopenia or thrombocytosis, polyclonal hypergammaglobulinemia, hypoalbuminemia, renal dysfunction, constitutional symptoms, effusions or edema, hepatosplenomegaly, eruptive cherry hemangiomas or violaceous papules, and lymphocytic interstitial pneumonitis. In the evaluation of lymphadenopathy across the spectrum of CD, patients can have a solitary enlarged lymph node or multiple enlarged lymph nodes within a single site (unicentric CD), multiple enlarged lymph nodes over 2 or more regional sites (oligocentric CD), or multiple enlarged lymph nodes over multiple lymph node stations with concomitant inflammatory signs/symptoms (multicentric CD). The assessment of lymph node histopathology can be subjective, and significant discordance among pathologists

occurs when the diagnostic histopathologic changes are observed to varying degrees. Further, significant inconsistency occurs in the determination of whether the constellation of histopathologic features is most consistent with the hypervascular or hyaline-vascular histopathologic subtype, the plasmacytic histopathologic subtype, or a mixed subtype involving aspects of both.¹³ Histopathologic changes in bone marrow have recently been reported, but they do not appear to be pathognomonic.¹⁴ Thus, a collaborative pathologic and clinical evaluation is necessary to diagnose iMCD properly, with evaluation at a high-volume center recommended. Herein, we present several cases to highlight important considerations in the diagnosis of iMCD, the exclusion of related conditions, and the treatment of patients with iMCD.

Case No. 1

A 37-year-old woman presented with palpable bilateral cervical lymphadenopathy of several months' duration. An excisional biopsy was interpreted as showing follicular hyperplasia "suggestive of CD," including atretic germinal centers, prominent vasculature, and expanded mantle zones. Beyond palpable cervical adenopathy, she had a history of recurrent sinusitis, burning mouth syndrome treated with corticosteroids, dry eyes, and a pruritic maculopapular rash. She had elevated inflammatory markers and a negative or normal complete blood cell count, complete metabolic panel, enzyme-linked immunosorbent assay (ELISA) for HIV, and IL-6 level. On the basis of the clinical and pathologic data, iMCD was diagnosed locally. Importantly, the result of an antinuclear antibody (ANA) test was positive, at 1:1280 dilution with a nuclear speckled pattern, and the anti-Sjögren syndrome A (SSA) and anti-SSB antibody index (AI) value was above 8.0. In addition, her family history was significant for a sister with lupus and maternal family members with autoimmune conditions.

Upon review of her outside pathology slides at the University of Pennsylvania, her top-line final diagnosis was confirmed as reactive follicular hyperplasia, although the comments clarified that the features previously interpreted as "suggestive" of CD were rather nonspecific and insufficient for the diagnosis. Given her symptoms of burning mouth syndrome and dry eyes, strong positivity for ANA and anti-SSA/SSB antibodies, and her family history of autoimmune conditions, reactive lymphadenopathy secondary to Sjögren syndrome was diagnosed instead and she was referred to rheumatology, where the diagnosis was confirmed and treatment initiated.

Discussion

The referral of a patient to a tertiary care center can facilitate

the diagnostic process when the pathology interpretations are discordant; therefore, the pathology findings should be reviewed at a high-volume center in such cases if time allows. Reactive histologic patterns, progressive transformation of germinal centers, nodular lymphocyte-predominant Hodgkin lymphoma, and peripheral T-cell lymphoma can all closely mimic the histology of CD. Furthermore, lymph node tissue can be heterogenous, making it difficult to determine which portion of a node best exemplifies its overall features. External pathologic review at an experienced center helps ensure an accurate pathologic diagnosis. However, urgent treatment should not be delayed during the weeks needed for an external pathology assessment, and care for a hospitalized or otherwise acutely ill patient should not be postponed. Altogether, it is hoped that the problem of discordant pathologic interpretations will be addressed as additional insight into the pathophysiology of CD is acquired, so that more specific markers and pathologic criteria can be developed.

Given the nonspecific nature of many pathologic findings in CD, a pathologist's interpretation that a lymph node exhibits CD histology is by itself insufficient for a diagnosis of iMCD. In this respect, the diagnosis of iMCD differs from the diagnosis of most malignancies and can confuse treating oncologists. The exclusion of other inflammatory conditions, such as infections and autoimmune disorders, is imperative before iMCD is diagnosed. Careful history taking is required for focal infectious symptoms (eg, dysuria, cough, and diarrhea) in addition to autoimmune manifestations such as arthralgias, morning stiffness, rash, and dry eye/dry mouth. A laboratory evaluation for infections with viral agents such as cytomegalovirus and Epstein-Barr virus and an autoimmune workup are also important in the context of the patient's presenting symptoms. It is conceivable that a patient with lymphadenopathy and a clear CD histology otherwise satisfies the criteria for another autoimmune condition or malignancy. In this conflicting situation, we favor treating the autoimmune condition or malignancy and not diagnosing concurrent iMCD. For example, a patient who meets the diagnostic criteria for systemic lupus erythematosus with prominent lupus nephritis should be treated accordingly, regardless of the presence of lymphadenopathy with CD histology, and IL-6–directed therapy for iMCD is probably not appropriate in this situation. The same principle applies for a patient with Hodgkin lymphoma who has neighboring lymph nodes and an inflammatory syndrome consistent with iMCD. However, when the history of an alternative diagnosis is remote (>5 years) and that condition is otherwise quiescent, we would favor diagnosing iMCD in a patient with the new onset of signs and symptoms and adenopathy consistent with iMCD.

Case No. 2

A 24-year-old man presented with palpable cervical adenopathy; subsequent positron emission tomography (PET)/computed tomography (CT) identified enlarged, mildly hypermetabolic cervical lymph nodes bilaterally. An excisional biopsy revealed CD with hyaline-vascular histology. The patient's oncologist treated him with 3 cycles of siltuximab (Sylvant, EUSA Pharma) for a presumed diagnosis of iMCD and judged his disease to be refractory owing to continuing shoulder pain and lymphadenopathy. This patient, however, had none of the following: inflammatory symptoms (fevers, night sweats, unexplained weight loss); clinical signs of inflammation (hepatosplenomegaly, fluid accumulation); biochemical markers of inflammation (elevated ESR/C-reactive protein [CRP], hypergammaglobulinemia, cytopenias); or evidence of organ dysfunction (elevated creatinine, hypoalbuminemia). Upon referral, we determined that this patient did *not* meet the diagnostic criteria for iMCD, despite the presence of at least 2 enlarged lymph nodes with consistent histology, because the clinical and laboratory criteria could not be satisfied. Given the oligocentric distribution of the lymphadenopathy and insufficient clinical and laboratory criteria, oligocentric CD was diagnosed, and he was referred for repeat imaging and the surgical removal of any residual enlarged, hypermetabolic adenopathy (similar to the treatment algorithm for unicentric CD).¹⁵

Discussion

Oligocentric CD is a recently described clinical entity that is poorly understood. It is most similar to unicentric CD, in which patients present with adenopathy in 2 to 3 adjacent lymph node stations (such as the bilateral cervical adenopathy in this patient) but do not satisfy the clinical or laboratory diagnostic criteria for iMCD.¹⁵ Like unicentric CD, oligocentric CD is potentially curable with complete surgical resection and should be treated according to the consensus treatment algorithms for unicentric CD.¹⁵ Thus, it is important that iMCD not be diagnosed purely on the basis of lymphadenopathy with consistent histology in at least 2 lymph node stations. Conversely, those patients with oligocentric lymphadenopathy who do meet iMCD minor criteria may benefit from iMCD-based treatments.¹⁶

How We Choose Therapy

The treatment of iMCD is complicated by a limited understanding of the etiology and pathogenesis.^{1,4,17} Work that established IL-6 as a key disease driver in a significant portion of patients led to the development and approval

of the anti-IL-6 therapy siltuximab, which is the only therapy approved by the US Food and Drug Administration (FDA) for iMCD and the only iMCD treatment ever to be evaluated in a randomized controlled trial.¹⁸⁻²¹ This double-blind, placebo-controlled, multicenter trial found a durable radiographic and symptomatic response rate of 34% in the siltuximab-treated patients and 0% in the placebo-treated patients, who were also allowed to receive corticosteroids and supportive care.²⁰ Tocilizumab (Actemra, Genentech), which inhibits the IL-6 receptor and thus has a mechanism of action similar to that of siltuximab, is approved for the treatment of iMCD in Japan and can be used in place of siltuximab when the latter agent is not available.²²

The CDCN consensus guidelines recommend first-line anti-IL-6 therapy with siltuximab for all patients with iMCD. Subsequent treatment and evaluation are determined according to the severity of illness. Disease is defined as severe if at least 2 of the following features are present: Eastern Cooperative Oncology Group (ECOG) performance status of at least 2, stage 4 renal dysfunction, extravascular fluid accumulation, hemoglobin level no higher than 8 g/dL, and evidence of pulmonary involvement (Figure 2).⁴ In practice, most patients with iMCD who require hospitalization for disease are likely to meet the criteria for severe disease.

Patients with severe iMCD should receive high-dose corticosteroids concurrently with siltuximab. Siltuximab should be administered on an accelerated weekly schedule for the first 4 cycles before the treatment is spaced to every 3 weeks (Figure 2).^{4,21,23-27} For a patient with severe disease that is causing neutropenia or thrombocytopenia, we would not delay siltuximab treatment and would provide support with transfusions and antibiotics as necessary. A daily assessment of the patient's disease status is essential. If evidence of disease progression develops in a patient with severe iMCD despite siltuximab, we recommend the prompt initiation of multiagent chemotherapy.²⁸⁻³¹

Although the consensus treatment guidelines recommend an individualized approach to the selection of chemotherapy, according to the patient's presentation, we often use concurrent rituximab, cyclophosphamide, and etoposide, which is similar to the regimens given for hemophagocytic lymphohistiocytosis (HLH), another immune hyperactivation disorder. Rituximab plus cyclophosphamide, doxorubicin, vincristine, and prednisone (R-CHOP) and rituximab plus cyclophosphamide, vincristine, and prednisone (RCVP) are reasonable alternatives.⁴ When chemotherapy is given to a patient with severe iMCD before 3 doses of siltuximab have been administered, we recommend continuing concurrent siltuximab.

For patients who have iMCD with mild or moderate

disease activity, siltuximab monotherapy administered every 3 weeks is the recommended first-line therapy.⁴ Tocilizumab is again a reasonable substitute when siltuximab is unavailable or not tolerated. Of note, a decrease in symptoms or inflammatory markers precedes improvement in organ function and regression of adenopathy. Although symptomatic and laboratory improvement can be seen within days to weeks after the initiation of siltuximab, the median time to radiographic response among responders in the phase 2 trial was approximately 4 months.²⁰ For this reason, a patient's disease should generally not be considered refractory to treatment until symptoms, biochemical laboratory markers of inflammation, and radiographic response of adenopathy have been assessed serially after at least 3 to 4 cycles of therapy.

The necessary duration of therapy for patients responding to IL-6-targeting therapy is currently unknown. Lifelong therapy is generally recommended because relapses were observed after discontinuation in patients in the phase 2 study that led to the FDA approval of siltuximab and in patients with iMCD who had been on tocilizumab in Japan. In our experience, the administration of siltuximab can be reduced to once every 6 weeks after a robust, durable response has been achieved for a sufficient period of time that the clinician feels comfortable spacing out dosing. Although no algorithm exists to guide treatment spacing, our experience is that spacing of dosing should not be done less than 12 months after the treatment was started, and there should be several months of evaluation for each dosing change to every 4 weeks, every 5 weeks, and every 6 weeks.^{4,20,25,26}

Patients with relatively high laboratory inflammatory marker levels tend to be more likely to respond to siltuximab.^{3,24} Given that a response was not achieved in 66% of the patients treated with siltuximab in the phase 2 trial, we have recently identified a 7-analyte panel that can predict which patients are likely to respond to siltuximab.³² Additional validation is needed before this panel can be implemented clinically. Of note, IL-6 levels should not be used to guide treatment decisions. In the phase 2 trial, some patients who had iMCD with low or normal IL-6 levels responded to siltuximab, and others with very elevated IL-6 levels did not respond. Importantly, the IL-6 levels of all patients treated with siltuximab or tocilizumab will show a spurious sharp increase following administration. Therefore, clinicians should not measure IL-6 levels or use IL-6 levels to inform a patient's disease status once anti-IL-6 therapy can be given.

For patients with mild or moderate disease that does not respond to siltuximab, we suggest enrollment in an open clinical trial, given the limited data on second-line therapies. We have been enrolling these patients in a clinical trial of sirolimus (NCT03933904), which was

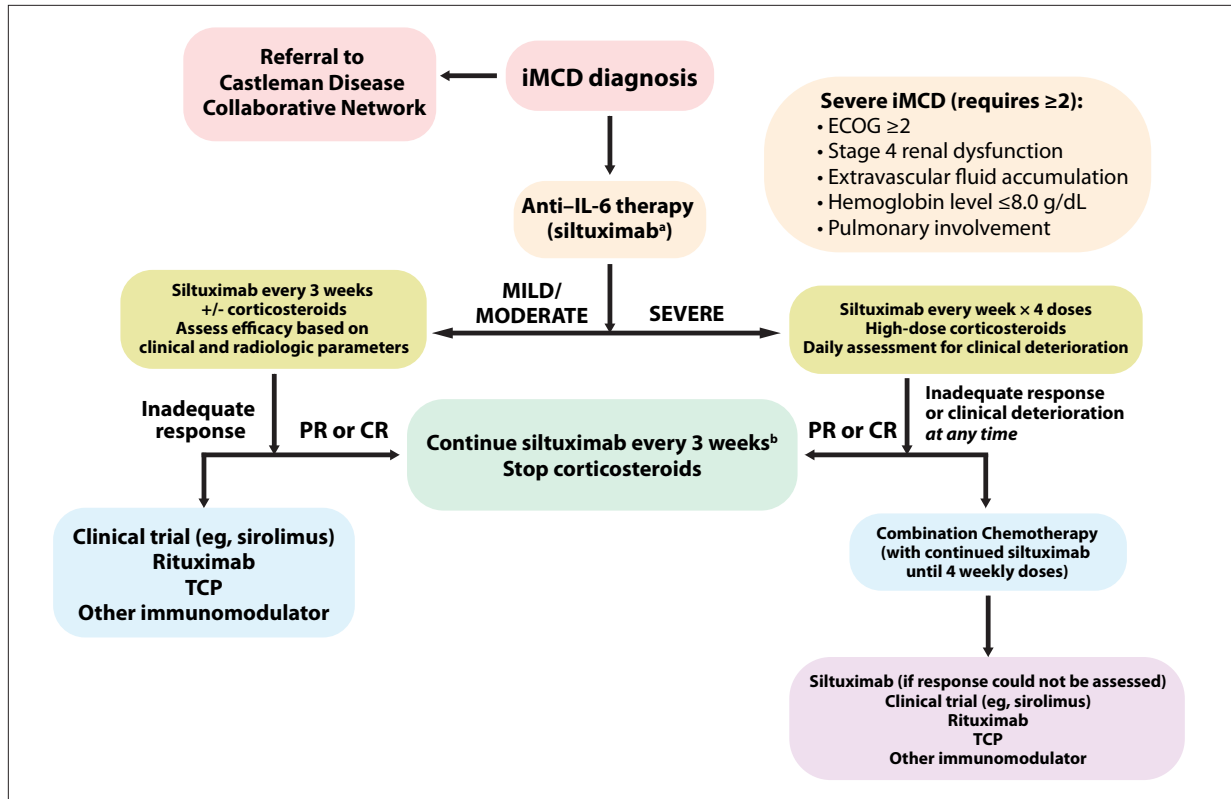


Figure 2. Upon a diagnosis of iMCD, patients should be referred to the Castleman Disease Collaborative Network. We also recommend an assessment for disease severity to determine the schedule of siltuximab administration and the dose intensity of corticosteroids. For a patient with severe iMCD, any worsening of organ function after siltuximab has been started should prompt a consideration of multiagent chemotherapy. Patients with severe iMCD in whom a PR or CR to siltuximab develops (symptoms and laboratory markers) can continue treatment weekly for 4 cycles before de-escalation to treatment every 3 weeks. Patients who have non-severe iMCD can be treated with siltuximab every 3 weeks, and if a long-term, durable remission is achieved, administration can be spaced to every 6 weeks. Patients whose disease is refractory to siltuximab should be considered for a clinical trial, such as the currently open trial of sirolimus (NCT03933904), or else they should be treated with rituximab or another immunomodulator in consultation with a clinician experienced in treating patients with iMCD.

^aTocilizumab can be substituted where siltuximab is unavailable.

^bIf a long-term, durable remission is achieved, clinicians can consider spacing administration up to every 6 weeks.

CR, complete response; ECOG, Eastern Cooperative Oncology Group Performance Status; iMCD, idiopathic multicentric Castleman Disease; PR, partial response; TCP, thalidomide, cyclophosphamide, and prednisone.

launched on the basis of translational research demonstrating increased mammalian target of rapamycin (mTOR) activation in a small cohort of patients with siltuximab-refractory iMCD that responded to sirolimus.³³⁻³⁵ Several alternatives are available for patients with siltuximab-refractory disease who are not eligible for enrollment in an open clinical trial. These include rituximab (with or without corticosteroids), given weekly for 4 cycles and then continued every 2 to 3 months as maintenance,^{2,4,36-40} or the off-label use of immunomodulatory agents such as sirolimus, ruxolitinib (Jakafi, Incyte),^{34,41} thalidomide (Thalomid, Celgene), cyclosporin A, and anakinra (Kineret, Sobi), which have been found to be

successful in limited case reports.^{32,42-48} Cytotoxic chemotherapy should be avoided in patients with mild or moderate iMCD to minimize treatment-related toxicity. We recommend consulting with a physician experienced in treating CD when a second-line therapy is selected. Ideally, all patients will be referred to the CDCN at the time of diagnosis and may already be connected with an expert clinician to ensure a timely and well-informed consultation. In addition, phase 2 data support the use of an entirely oral regimen of thalidomide in combination with cyclophosphamide and prednisone (TCP).⁴⁹ Data from the same group also highlighted a role for bortezomib, cyclophosphamide, and dexamethasone (BCD) in

patients with iMCD, particularly patients with plasmacytic or mixed histopathologic subtypes.⁵⁰ This regimen proved active against iMCD, although the study included only 2 patients whose disease had previously failed to respond to IL-6–targeted therapy, so its applicability to patients with disease refractory to IL-6–targeted therapy is unknown. Nevertheless, these 2 studies provide data in support of the use of TCP or BCD in certain patients with iMCD, particularly those who cannot access siltuximab or tocilizumab.

Importantly, all patients should be instructed to connect with the CDCN upon diagnosis (www.CDCN.org, info@castlemannetwork.org), so that they can learn about their illness, connect with a CD-experienced specialist in a timely manner should an urgent consultation later become necessary, connect with the larger CD patient community, and be informed about opportunities to contribute medical data to the ACCELERATE Castleman disease registry (www.CDCN.org/ACCELERATE) and contribute blood and/or lymph node tissue to research.⁵¹

Case No. 3

A 31-year-old woman presented with nausea and vomiting, abdominal pain, dyspnea, fatigue, fever, and unintentional weight loss. Radiology identified generalized lymphadenopathy above and below the diaphragm, and laboratory tests revealed thrombocytopenia, anemia, an elevated ESR, hypoalbuminemia, and renal dysfunction, with normal gamma globulin levels. The result of an excisional biopsy of a cervical lymph node was consistent with HHV8-negative CD. On the basis of these findings, iMCD-TAFRO was diagnosed, and the patient was promptly treated with siltuximab and high-dose corticosteroids. This regimen rapidly reduced her inflammatory markers and symptoms before her end-organ function improved. Ultimately, at 6 years, a complete radiographic remission has been achieved while the patient continues taking siltuximab, which is currently spaced out to every 6 weeks.

Discussion

This case demonstrates the importance of using siltuximab as first-line therapy for severe disease, as well as the potential for spacing out doses of siltuximab when patients are responding well. Despite the severity of this patient's disease, siltuximab and high-dose corticosteroids successfully induced a complete response without the need for cytotoxic chemotherapy. A recent study found that of the 60 patients in the long-term extension study of the phase 1 and phase 2 siltuximab trials (median duration, 5.5 years), 25 extended their dosing to every 6 weeks, and only one patient demonstrated evidence

of disease progression, which remitted when dosing was returned to every 3 weeks.²⁵

Case No. 4

A 47-year-old man with nausea and vomiting, fevers, and fatigue was admitted to intensive care with hypotension, hypoxemic respiratory failure, and acute renal failure requiring continuous renal replacement therapy for volume overload. He was found to have thrombocytopenia, anasarca, elevated inflammatory markers, widespread mildly enlarged and mildly hypermetabolic lymphadenopathy, and patchy lung opacities bilaterally. The results of an excisional biopsy of a left axillary lymph node were consistent with HHV8-negative CD. iMCD-TAFRO was diagnosed, and the patient was considered to have severe iMCD. He was started on high-dose corticosteroids and siltuximab, with substantial clinical improvement. Serial evaluations noted resolution of the inflammatory marker elevation, thrombocytopenia, oxygen requirement, kidney failure, anasarca, and adenopathy. After a long rehabilitation stay, he was able to return home. For 3 months, he remained in remission while continuing siltuximab. Increasing abdominal distension and dyspnea then developed, and he was again found to have worsening thrombocytopenia and kidney injury with increasing inflammatory marker elevation, adenopathy, ascites, and pleural effusions, so that readmission for relapsed, severe iMCD was required. The patient was treated with rituximab, cyclophosphamide, and etoposide while hospitalized. He was then readmitted electively to complete 6 total cycles of treatment, achieving a complete response. He continued rituximab maintenance therapy every 8 to 12 weeks for 2 years. He has remained in remission without therapy for the past 3 years, with no symptoms or laboratory/radiologic evidence of disease.

Discussion

This case demonstrates the need for the prompt initiation of multiagent chemotherapy for severe, siltuximab-refractory iMCD. Furthermore, it shows that after resolution of the severe manifestations of disease with chemotherapy, a second-line therapy for nonsevere disease should be pursued. Relapse following an initial response to siltuximab is fortunately rare, however. Patients who respond initially to siltuximab tend to have durable responses. For instance, of the patients who achieved a response according to the criteria of the siltuximab phase 1 and phase 2 trials and who were included in the long-term safety extension study, 97% had maintained disease control at their last study assessment, and 70% were followed for the full 6 years of the study.²⁰

Case No. 5

A 29-year-old man presented with chest and back pain, drenching night sweats, and fatigue. He was found to have a mediastinal mass; multifocal, mildly enlarged lymphadenopathy above and below the diaphragm; elevated ESR and CRP; and mild anemia. Biopsy of the mediastinal mass revealed the hyaline-vascular histopathologic subtype of CD. The patient was started on siltuximab for nonsevere iMCD, with no improvement after 4 cycles of treatment. He was then treated with 6 weekly doses of rituximab plus prednisone, after which a partial radiographic response (including a 50% reduction in the size of the mediastinal mass) and a complete symptomatic response were noted. After several months, his symptoms recurred, along with rising inflammatory biomarkers and increasing hypermetabolic activity in his existing adenopathy. The initiation of sirolimus resulted in a symptomatic and biochemical partial response, in addition to stable radiographic disease. The acne that developed while he was on sirolimus resolved with doxycycline, and he has otherwise continued to tolerate therapy well for the past year.

Discussion

Even if nonsevere, iMCD should still be treated with first-line siltuximab, although another treatment, such as rituximab (with corticosteroids) or sirolimus, can be pursued for patients with refractory disease.^{4,17,31} The treatment of disease refractory to siltuximab and rituximab remains an unmet medical need for patients with iMCD. Whenever appropriate, we recommend enrolling patients in a clinical trial, such as the one currently open for sirolimus in anti-IL-6-refractory patients (NCT03933904).

Conclusion

To treat patients with iMCD effectively, we recommend a careful confirmation of the diagnosis with the exclusion of alternative diagnoses and other forms of CD. When time allows, pathologic confirmation should be obtained at an experienced center, given the high number of discordant interpretations. Although siltuximab is the first-line therapy for all patients with iMCD, we recommend that the severity of disease be determined at diagnosis and the therapeutic approach guided accordingly. We recommend starting with 4 weekly doses of siltuximab and high-dose corticosteroids for severe iMCD. Furthermore, patients with severe iMCD should be treated with multiagent chemotherapy at the first signs of disease progression or refractory cytokine storm after siltuximab has been initiated. Patients with mild or moderate disease should start with siltuximab every 3 weeks, and if their disease

proves to be refractory, they should either enroll in a clinical trial in the second line or receive rituximab or other immunomodulators. All patients should be encouraged to join the CDCN at diagnosis (or earlier if CD is strongly suspected), and an additional immunomodulatory agent should be selected in consultation with a CD-experienced physician for patients with siltuximab-refractory disease.

Together, these recommendations highlight the diagnostic and therapeutic challenges still confronting patients with CD and their clinicians. Extensive progress led to the first consensus diagnostic and treatment guidelines for iMCD and the development of the first FDA-approved medication for CD. However, the underlying etiology and pathophysiology of CD remain largely unknown, confounding efforts to develop specific diagnostic tests that do not rely heavily on pathologist interpretation or the exclusion of alternative diagnoses.^{52,53} Additional insight into the pathogenesis of CD would also facilitate the development of new treatments, which are badly needed for the majority of patients, whose disease is likely to be refractory to first-line siltuximab. We hope this review will provide accessible guidance to treating clinicians to ensure the standardization of high-quality care for patients with CD. We also strongly recommend referral to the CDCN to streamline patient care and support ongoing, much-needed research efforts into advancing CD diagnostics and therapies.

Disclosures

Dr Fajgenbaum has received research funding and consulting fees from EUSA Pharma, and receives funding support from the National Heart, Lung, and Blood Institute (R01HL141408) and the Castleman Disease Collaborative Network. Dr Brandstadter receives funding support from the American Society of Hematology; he has no competing interests to declare.

Acknowledgments

The authors would like to thank Drs Sunita Nasta and Ivan Maillard for their mentorship and critical feedback on this manuscript.

References

1. Fajgenbaum DC, Shilling D. Castleman disease pathogenesis. *Hematol Oncol Clin North Am.* 2018;32(1):11-21.
2. Liu AY, Nabel CS, Finkelman BS, et al. Idiopathic multicentric Castleman's disease: a systematic literature review. *Lancet Haematol.* 2016;3(4):e163-e175.
3. Fajgenbaum DC, Uldrick TS, Bagg A, et al. International, evidence-based consensus diagnostic criteria for HHV-8-negative/idiopathic multicentric Castleman disease. *Blood.* 2017;129(12):1646-1657.
4. van Rhee F, Voorhees P, Dispenzieri A, et al. International, evidence-based consensus treatment guidelines for idiopathic multicentric Castleman disease. *Blood.* 2018;132(20):2115-2124.
5. Munshi N, Mehra M, van de Velde H, Desai A, Potluri R, Vermeulen J. Use of a claims database to characterize and estimate the incidence rate for Castleman

- disease. *Leuk Lymphoma*. 2015;56(5):1252-1260.
6. Mukherjee S, Martin R, Sande B, Paige JS, Fajgenbaum DC. Epidemiology and treatment patterns of idiopathic multicentric Castleman disease in the era of IL-6-directed therapy. *Blood Adv*. 2022;6(2):359-367.
 7. Fajgenbaum DC, June CH. Cytokine storm. *N Engl J Med*. 2020;383(23):2255-2273.
 8. Pierson SK, Stonestrom AJ, Shilling D, et al. Plasma proteomics identifies a 'chemokine storm' in idiopathic multicentric Castleman disease. *Am J Hematol*. 2018;93(7):902-912.
 9. Nishimura Y, Fajgenbaum DC, Pierson SK, et al. Validated international definition of the thrombocytopenia, anasarca, fever, reticulin fibrosis, renal insufficiency, and organomegaly clinical subtype (TAFRO) of idiopathic multicentric Castleman disease. *Am J Hematol*. 2021;96(10):1241-1252.
 10. Fajgenbaum DC, Ruth JR, Kelleher D, Rubenstein AH. The collaborative network approach: a new framework to accelerate Castleman's disease and other rare disease research. *Lancet Haematol*. 2016;3(4):e150-e152.
 11. Uldrick TS, Polizzotto MN, Aleman K, et al. Rituximab plus liposomal doxorubicin in HIV-infected patients with KSHV-associated multicentric Castleman disease. *Blood*. 2014;124(24):3544-3552.
 12. Dispenzieri A. POEMS syndrome: 2017 Update on diagnosis, risk stratification, and management. *Am J Hematol*. 2017;92(8):814-829.
 13. Fajgenbaum DC, Wu D, Goodman A, et al; Castleman Disease Collaborative Network Scientific Advisory Board diagnostic criteria international working group and treatment guidelines international working group. Insufficient evidence exists to use histopathologic subtype to guide treatment of idiopathic multicentric Castleman disease. *Am J Hematol*. 2020;95(12):1553-1561.
 14. Belyaeva E, Rubenstein A, Pierson SK, et al. Bone marrow findings of idiopathic Multicentric Castleman disease: A histopathologic analysis and systematic literature review. *Hematol Oncol*. 2022;40(2):191-201.
 15. van Rhee F, Oksenhendler E, Skralovic G, et al. International evidence-based consensus diagnostic and treatment guidelines for unicentric Castleman disease. *Blood Adv*. 2020;4(23):6039-6050.
 16. Zhang MY, Jia MN, Chen J, et al. UCD with MCD-like inflammatory state: surgical excision is highly effective. *Blood Adv*. 2021;5(1):122-128.
 17. Yoshizaki K. A reference guide for management of Castleman disease. *Rinsho Ketsueki*. 2017;58(2):97-107.
 18. Yoshizaki K, Murayama S, Ito H, Koga T. The role of interleukin-6 in Castleman disease. *Hematol Oncol Clin North Am*. 2018;32(1):23-36.
 19. Fajgenbaum DC, Kurzrock R. Siltuximab: a targeted therapy for idiopathic multicentric Castleman disease. *Immunotherapy*. 2016;8(1):17-26.
 20. van Rhee F, Wong RS, Munshi N, et al. Siltuximab for multicentric Castleman's disease: a randomised, double-blind, placebo-controlled trial. *Lancet Oncol*. 2014;15(9):966-974.
 21. Katsume A, Saito H, Yamada Y, et al. Anti-interleukin 6 (IL-6) receptor antibody suppresses Castleman's disease like symptoms emerged in IL-6 transgenic mice. *Cytokine*. 2002;20(6):304-311.
 22. Nishimoto N, Kanakura Y, Aozasa K, et al. Humanized anti-interleukin-6 receptor antibody treatment of multicentric Castleman disease. *Blood*. 2005;106(8):2627-2632.
 23. Lang E, Sande B, Brodtkin S, van Rhee F. Idiopathic multicentric Castleman disease treated with siltuximab for 15 years: a case report [published online March 2, 2022]. *Ther Adv Hematol*. doi:10.1177/20406207221082552.
 24. Morra DE, Pierson SK, Shilling D, et al. Predictors of response to anti-IL6 monoclonal antibody therapy (siltuximab) in idiopathic multicentric Castleman disease: secondary analyses of phase II clinical trial data. *Br J Haematol*. 2019;184(2):232-241.
 25. van Rhee F, Casper C, Voorhees PM, et al. Long-term safety of siltuximab in patients with idiopathic multicentric Castleman disease: a prespecified, open-label, extension analysis of two trials. *Lancet Haematol*. 2020;7(3):e209-e217.
 26. van Rhee F, Casper C, Voorhees PM, et al. A phase 2, open-label, multicenter study of the long-term safety of siltuximab (an anti-interleukin-6 monoclonal antibody) in patients with multicentric Castleman disease. *Oncotarget*. 2015;6(30):30408-30419.
 27. van Rhee F, Rossi JF, Simpson D, et al. Newly diagnosed and previously treated multicentric Castleman disease respond equally to siltuximab. *Br J Haematol*. 2021;192(1):e28-e31.
 28. Zhu SH, Yu YH, Zhang Y, Sun JJ, Han DL, Li J. Clinical features and outcome of patients with HIV-negative multicentric Castleman's disease treated with combination chemotherapy: a report on 10 patients. *Med Oncol*. 2013;30(1):492.
 29. Herrada J, Cabanillas F, Rice L, Manning J, Pugh W. The clinical behavior of localized and multicentric Castleman disease. *Ann Intern Med*. 1998;128(8):657-662.
 30. Iwaki N, Fajgenbaum DC, Nabel CS, et al. Clinicopathologic analysis of TAFRO syndrome demonstrates a distinct subtype of HHV-8-negative multicentric Castleman disease. *Am J Hematol*. 2016;91(2):220-226.
 31. Dong Y, Zhang L, Nong L, et al. Effectiveness of rituximab-containing treatment regimens in idiopathic multicentric Castleman disease. *Ann Hematol*. 2018;97(9):1641-1647.
 32. Pierson SK, Shenoy S, Oromendia AB, et al. Discovery and validation of a novel subgroup and therapeutic target in idiopathic multicentric Castleman disease. *Blood Adv*. 2021;5(17):3445-3456.
 33. Arenas DJ, Floess K, Kobrin D, et al. Increased mTOR activation in idiopathic multicentric Castleman disease. *Blood*. 2020;135(19):1673-1684.
 34. Pai RL, Japp AS, Gonzalez M, et al. Type I IFN response associated with mTOR activation in the TAFRO subtype of idiopathic multicentric Castleman disease. *JCI Insight*. 2020;5(9):135031.
 35. Fajgenbaum DC, Langan RA, Japp AS, et al. Identifying and targeting pathogenic PI3K/AKT/mTOR signaling in IL-6-blockade-refractory idiopathic multicentric Castleman disease. *J Clin Invest*. 2019;129(10):4451-4463.
 36. Ocio EM, Sanchez-Guijo FM, Diez-Campelo M, et al. Efficacy of rituximab in an aggressive form of multicentric Castleman disease associated with immune phenomena. *Am J Hematol*. 2005;78(4):302-305.
 37. Ide M, Kawachi Y, Izumi Y, Kasagi K, Ogino T. Long-term remission in HIV-negative patients with multicentric Castleman's disease using rituximab. *Eur J Haematol*. 2006;76(2):119-123.
 38. Mian H, Leber B. Mixed variant multicentric Castleman disease treated with rituximab: case report. *J Pediatr Hematol Oncol*. 2010;32(8):622.
 39. Yu L, Tu M, Cortes J, et al. Clinical and pathological characteristics of HIV- and HHV-8-negative Castleman disease. *Blood*. 2017;129(12):1658-1668.
 40. Oksenhendler E, Boutboul D, Fajgenbaum D, et al. The full spectrum of Castleman disease: 273 patients studied over 20 years. *Br J Haematol*. 2018;180(2):206-216.
 41. Lust H, Gong S, Remiker A, Rosoff J. Idiopathic multicentric Castleman disease with TAFRO clinical subtype responsive to IL-6/JAK inhibition: a pediatric case series. *Pediatr Blood Cancer*. 2021;68(10):e29261.
 42. Koga T, Takemori S, Hagimori N, et al. An open-label continuation trial of sirolimus for tocilizumab-refractory idiopathic multicentric Castleman disease: study protocol for an investigator-initiated, multicenter, open-label trial (SPIRIT compliant). *Medicine (Baltimore)*. 2020;99(50):e23291.
 43. Koga T, Hagimori N, Takemori S, et al. Randomized, double-blind, placebo-controlled, parallel-group trial of sirolimus for tocilizumab-resistant idiopathic multicentric Castleman disease: study protocol for clinical trial. *Medicine (Baltimore)*. 2020;99(30):e20710.
 44. Inoue M, Ankou M, Hua J, Iwaki Y, Hagihara M, Ota Y. Complete resolution of TAFRO syndrome (thrombocytopenia, anasarca, fever, reticulin fibrosis and organomegaly) after immunosuppressive therapies using corticosteroids and cyclosporin A: a case report. *J Clin Exp Hematop*. 2013;53(1):95-99.
 45. Yamaga Y, Tokuyama K, Kato T, et al. Successful treatment with cyclosporin A in tocilizumab-resistant TAFRO syndrome. *Intern Med*. 2016;55(2):185-190.
 46. Galeotti C, Tran TA, Franchi-Abella S, Gabre M, Pariente D, Koné-Paut I. IL-1RA agonist (anakinra) in the treatment of multifocal Castleman disease: case report. *J Pediatr Hematol Oncol*. 2008;30(12):920-924.
 47. El-Osta H, Janku F, Kurzrock R. Successful treatment of Castleman's disease with interleukin-1 receptor antagonist (Anakinra). *Mol Cancer Ther*. 2010;9(6):1485-1488.
 48. Chen LYC, Skinnider BF, Wilson D, Fajgenbaum DC. Adrenalitis and anasarca in idiopathic multicentric Castleman's disease. *Lancet*. 2021;397(10286):1749.
 49. Zhang L, Zhao A-L, Duan M-H, et al. Phase 2 study using oral thalidomide-cyclophosphamide-prednisone for idiopathic multicentric Castleman disease. *Blood*. 2019;133(16):1720-1728.
 50. Zhang L, Zhang MY, Cao XX, et al. A prospective, multicenter study of bortezomib, cyclophosphamide, and dexamethasone in relapsed/refractory iMCD. *Leuk Lymphoma*. 2022;63(3):618-626.
 51. Pierson SK, Khor JS, Zigar J, et al. ACCELERATE: a patient-powered natural history study design enabling clinical and therapeutic discoveries in a rare disorder. *Clin Rep Med*. 2020;1(9):100158.
 52. Nabel CS, Sameroff S, Shilling D, et al. Virome capture sequencing does not identify active viral infection in unicentric and idiopathic multicentric Castleman disease. *PLoS One*. 2019;14(6):e0218660.
 53. Fajgenbaum DC. Novel insights and therapeutic approaches in idiopathic multicentric Castleman disease. *Blood*. 2018;132(22):2323-2330.